

Correlation between CA-15-3 and Bone Scan Findings in Patients with Carcinoma Breast

Julekha Khatun, Tarim Mahmood

Rajshahi Medical College and Hospital, Bangladesh.

Abstract

Objectives: Breast cancer is the most common malignant tumor of females; the incidence increases with age. Bone is the most common site to which breast cancer metastasizes. Between 30% to 85% of patients with metastatic breast cancer develop bone metastases during the course of the disease. Carbohydrate antigen (CA) 15-3 is a circulating human breast cancer associated antigen used as a tumor marker in the screening of breast cancer patients for metastasis. The objective of this study was to compare the levels of CA 15-3 and bone scan findings in patients with breast cancer. **Material and Methods:** This cross-sectional analytical study was carried out at Rajshahi medical college hospital, Rajshahi, from January 2018 to December 2019. A total of 90 diagnosed breast cancer patients were enrolled in this study. Among them 45 patient was with normal CA 15-3 level and 45 patient was with elevated CA 15-3 level. All of them underwent bone scan. The tumor marker CA 15-3 was compared with bone scan findings. **Results:** Mean age of the patients was 46.62 ± 8.67 years (range 33 to 67 years). Among 45 patients with normal CA 15-3 level, bone scan was negative for metastasis in 39 (86.66%) patients with CA 15-3 level 14.96 ± 9.72 U/ml and positive for metastasis in 6 (13.33%) patient with CA 15-3 level 23.3 ± 2.96 U/ml. Out of 45 patients with elevated CA 15-3 level 11 (24.44%) had negative bone scan with CA 15-3 level 92.5 ± 19.89 U/ml whereas 34 (75.55%) patient had positive bone scan findings with CA 15-3 level 413.83 ± 362.83 U/ml. In current study, Pearson's correlation coefficient test showed positive relation, for elevated CA 15-3 level and Bone scan findings there was ($r = 0.853$, $p = 0.00001$) and for normal CA15-3 level and bone scan finding ($r = 0.449$, $p = 0.0019$). **Conclusion:** The result of this study showed positive relationship between the bone scan findings and CA 15-3 level of breast carcinoma patients.

Keywords: Carcinoma Breast- CA 15-3 level- Bone scan

Asian Pac J Cancer Biol, 7 (2), 121-123

Submission Date: 03/10/2022 Acceptance Date: 04/16/2022

Introduction

Breast cancer is the most frequent female cancer, especially in 'developed' countries. Incidence of breast cancer varies geographically (20-30 cases per 100,000 women in South-Central Asia) [1]. Bone is the most common site to which breast cancer metastasizes. About 30% to 85% of patients with metastatic breast cancer develop bone metastases during the course of the disease. Bone also represents the first site of metastasis for 26% to 50% of patients with metastatic breast cancer. Complications of bone metastasis include bone pain, pathologic fractures (the incidence of which ranges from 16% to 60%), hypercalcemia, and spinal cord compression, any of which can profoundly impair

quality of life [2-6]. The detection of bone metastasis accurately reflects the prognosis and the early detection in the asymptomatic case may alert the clinician to the possible complications inherit in skeletal destruction [7,8]. Radioisotope bone scintigraphy is the most sensitive and the most common method for screening bony metastasis. Carbohydrate antigen 15-3 (CA 15-3) is a tumor marker commonly used in the screening breast cancer patients for metastasis and monitoring treatment response [9-11]. The aim of this study was to find out the relation between bone metastasis and CA15-3 level.

Corresponding Author:

Dr. Tarim Mahmood
Beacon Pharmaceuticals Ltd, Bangladesh.
Email: drtarim-onco@beaconpharma.com.bd

Materials and Methods

This analytical cross-sectional study was carried out in the Rajshahi medical college hospital, Rajshahi, from January 2018 to December 2019. A total of 90 diagnosed breast cancer patients were enrolled in this study. Among them 45 patients were with normal CA 15-3 level and 45 patients were with elevated CA 15-3 level. All of them underwent bone scan. Bone scan was performed 2 hours after intravenous injection of 20 mCi of ^{99m}Tc methylene diphosphonate (^{99m}Tc MDP). Biological reference interval of CA 15-3 was <31.30 U/ml. The collected data were compiled and analyzed using computer-based software SPSS program. Bivariate analysis such as Pearson's correlation coefficient test were performed to find out the association between two variables. In this analysis level of significance was 0.05 and p value ≤ 0.05 was considered as statistically significant.

Results

Total 90 primary breast carcinoma patients with mean \pm SD age 46.62 ± 8.67 years (range, 33 to 67 years) were enrolled in this study. The bar diagram showed the distribution of the carcinoma breast patients at different age groups (Figure 1)

Among 45 patients with normal CA 15-3 level, bone scan was negative for metastasis in 39 (86.66%) patients (mean \pm SD of CA 15.3 was 14.96 ± 9.72 U/ml) and positive for metastasis in 6 (13.33%) patients (mean \pm SD of CA 15.3 was 23.3 ± 2.96) (Table 1). To see the relationship between CA 15-3 and bone scan, Pearson's correlation coefficient test was done and positive relation ($p = 0.0019$, $r = 0.449$) was observed between the two variables. The result was statistically significant ($p < 0.05$).

Among 45 patients with elevated serum CA 15-3, bone scan was negative for metastasis in 11 (24.44%) patients (mean \pm SD of CA 15.3 was 92.5 ± 19.89 U/ml) and positive for metastasis in 34 (75.55%) patients (mean \pm SD of CA 15.3 was U/ml) (Table 2). To see the relationship between CA 15-3 and bone scan, Pearson's correlation coefficient test was done and positive relation ($p = 0.00001$, $r = 0.853$) was observed between the two variables. The result was statistically significant ($p < 0.05$).

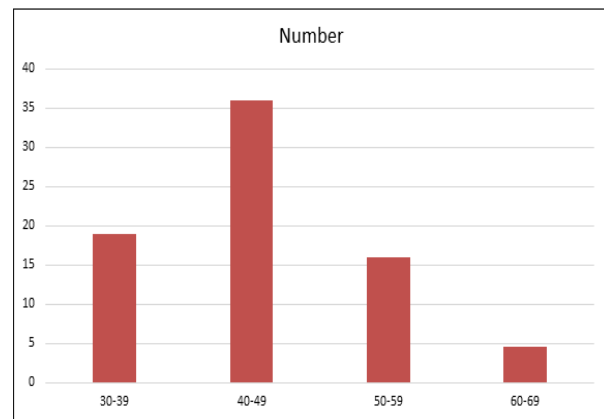


Figure 1. Bar Diagram of Distribution the Carcinoma Patients in Different Age Groups

Discussion

Bone is known to be one of the most common sites of metastasis for breast cancer patients. Several imaging modalities, including plain radiography, computed tomography, magnetic resonance imaging, SPECT-bone scan and positron emission tomography are available to detect bone metastasis. Compared to other modalities, bone scan is characteristic by its high sensitivity, easy accessibility, and providing whole-body imaging of bone metabolism [12,13]. Elevated CA 15-3 tumor markers sometimes provide evidence on undiagnosed metastasis in patients with breast cancer [14-16].

In this study Among 45 patients with normal CA 15-3 level, bone scan was negative for metastasis in 39 (86.66%) patients with CA 15-3 level 14.96 ± 9.72 U/ml and positive for metastasis in 6 (13.33%) patient with CA 15-3 level 23.3 ± 2.96 U/ml. The study done by Ghadge et al (2012) showed similar results that out of 70 patients, 55 (78%) had normal value of CA 15-3, whereas 53 (75%) had negative bone scans and 17 (25%) had positive bone scans [17]. Current study showing 6 (13.33%) patients had positive bone scan with normal CA 15-3 level although Tomlinson et al (1995) reported no patients with normal CA 15-3 had bone metastasis [11].

In this study, out of 45 patients with elevated CA 15-3 level 11 (24.44%) patients had negative bone scan with CA 15-3 level 92.5 ± 19.89 U/ml whereas 34 (75.55%) patients had positive bone scan findings with CA 15-3 level 413.83

Table 1. The Distribution of Patients with Normal CA 15-3 Level According to Bone Scan Findings (n = 45)

Bone Scan Results	Number of patients (%)	CA 15-3 Value U/ml
		Mean \pm SD
Negative for Metastasis	39 (86.66)	14.96 ± 9.72
Positive for Metastasis	6 (13.33)	23.3 ± 2.96

Table 2. Distribution of Patients with Elevated Serum CA 15-3 Level According to Bone Scan Findings (n = 45)

Bone Scan Results	Number of Patients (%)	CA 15-3 Value U/ml
		Mean \pm SD
Positive for Metastasis	34 (75.55)	413.83 ± 362.83
Negative for Metastasis	11 (24.44)	92.5 ± 19.89

± 362.83 U/ml. This finding was similar with a study conducted by Ghadge et al (2012). They showed that out of 70 patients 15 had elevated CA 15-3 level among them 6 had negative bone scan with CA 15-3 level 74.8 ± 47.8 whereas 9 patients had positive bone scan with CA 15-3 level 346.6 ± 313.7 U/ml [17]. In current study, Pearson's correlation coefficient test showed positive relation, for elevated CA 15-3 level and Bone scan findings that was ($r = 0.853$, $p = 0.00001$) and for normal CA15-3 level and bone scan finding ($r = 0.449$, $p = 0.0019$). This finding was compatible with the study done by Begic et al (2006). They showed the weakly positive ($r = 0.096$, $p = 0.323$) relationship with bone scan findings with CA15-3 level.

In conclusion, Current study showed positive correlation between CA 15-3 level and Bone scan findings in patients with breast cancers. Therefore, CA 15-3 level can be used as a preliminary tool for screening to select patients who needs radionuclide bone scan.

References

- Hosen M, Begum N, Hossain M, Ahmed P, Mutsuddy P, Chowdhury S. Tc-99m MDP Bone Scan Evaluation in Breast Cancer: A Study on 425 Patients. *Medicine Today*. 2018 Aug 8;30(2):49-52.
- Galasko C. Skeletal metastases and mammary cancer. *Annals of the Royal College of Surgeons of England*. 1972 Jan;50(1):3.
- V S, Au B, Ti S, Gn H. Clinical course of breast cancer patients with osseous metastasis treated with combination chemotherapy. *Cancer*. 1986 Dec 15;58(12). [https://doi.org/10.1002/1097-0142\(19861215\)58:12<2589::aid-cncr2820581206>3.0.co;2-o](https://doi.org/10.1002/1097-0142(19861215)58:12<2589::aid-cncr2820581206>3.0.co;2-o)
- Coleman RE, Rubens RD. The clinical course of bone metastases from breast cancer. *British Journal of Cancer*. 1987 01;55(1):61-66. <https://doi.org/10.1038/bjc.1987.13>
- Fisher B, Ravdin RG, Ausman RK, Slack NH, Moore GE, Noer RJ. Surgical adjuvant chemotherapy in cancer of the breast: results of a decade of cooperative investigation. *Annals of Surgery*. 1968 09;168(3):337-356. <https://doi.org/10.1097/0000658-196809000-00004>
- Hortobagyi GN. Novel approaches to the management of bone metastases in patients with breast cancer. *Seminars in Oncology*. 2002 06;29(3 Suppl 11):134-144. <https://doi.org/10.1053/sonc.2002.34066>
- Begić A, Kucukalić-Selimović E, Obralić N, Durić O, Lacević N, Skopljak A. Correlation between bone scintigraphy and tumor markers in patients with breast carcinoma. *Bosnian Journal of Basic Medical Sciences*. 2006 02;6(1):75-77. <https://doi.org/10.17305/bjbms.2006.3216>
- Gedik G, Kiratli P, Tascioglu B, Aras T. Comparison of bone scintigraphy with serum tumor markers of CA 15-3 and carcinoembryonic antigen in patients with breast carcinoma. *Saudi medical journal*. 2006 Mar 1;27(3):317.
- Sharmin S, Haque J, ur Rahman M, Rahman H, Hossain J, Uddin M, Ferdous J, Yasmin F. Correlation between Bone Scan Findings and CA 153 in Patients with Carcinoma Breast. *Bangladesh Journal of Nuclear Medicine*. 2017;20(1):24-6.
- M M, HA, Ag Z. Comparison of bone scan with carbohydrate antigen 15-3 for evaluation of bone metastasis of breast cancer. *Pakistan journal of biological sciences : PJBS*. 2010 02 15;13(4). <https://doi.org/10.3923/pjbs.2010.175.179>
- Ip T, A W, Ja B, Jk K. Tumour marker CA15-3: possible uses in the routine management of breast cancer. *European journal of cancer (Oxford, England : 1990)*. 1995 06;31A(6). [https://doi.org/10.1016/0959-8049\(94\)00447-1](https://doi.org/10.1016/0959-8049(94)00447-1)
- Solomayer EF, Diel IJ, Meyberg GC, Gollan C, Bastert G. Metastatic breast cancer: clinical course, prognosis and therapy related to the first site of metastasis. *Breast Cancer Research and Treatment*. 2000 02;59(3):271-278. <https://doi.org/10.1023/a:1006308619659>
- Costelloe CM, Rohren EM, Madewell JE, Hamaoka T, Theriault RL, Yu T, Lewis VO, Ma J, Stafford RJ, Tari AM, Hortobagyi GN, Ueno NT. Imaging bone metastases in breast cancer: techniques and recommendations for diagnosis. *The Lancet. Oncology*. 2009 06;10(6):606-614. [https://doi.org/10.1016/S1470-2045\(09\)70088-9](https://doi.org/10.1016/S1470-2045(09)70088-9)
- Agyei Frempong MT, Darko E, Addai BW. The use of carbohydrate antigen (CA) 15-3 as a tumor marker in detecting breast cancer. *Pakistan journal of biological sciences: PJBS*. 2008 08 01;11(15):1945-1948. <https://doi.org/10.3923/pjbs.2008.1945.1948>
- Pd B, As G, Jp C, Jp V, C C, C A, D F. Can tumour marker assays be a guide in the prescription of bone scan for breast and lung cancers?. *European journal of nuclear medicine*. 1999 01;26(1). <https://doi.org/10.1007/s002590050352>
- Pr K, Jt A, Jd B, Is R, M L, K M, Jf F. An analysis of bone scintigraphy in early (operable) breast cancer. *The Australian and New Zealand journal of surgery*. 1979 06;49(3). <https://doi.org/10.1111/j.1445-2197.1979.tb07671.x>
- Ms G, Pp N, Bp T, Rm H, Tj M. A Comparative Study of Bone Scan Findings and Serum Levels of Tumor Marker CA15-3 in Patients with Breast Carcinoma. *Indian journal of clinical biochemistry : IJCB*. 2012 01;27(1). <https://doi.org/10.1007/s12291-011-0168-5>



This work is licensed under a Creative Commons Attribution-Non Commercial 4.0 International License.