

The Paraganglioma of the Bladder in a Patient with Von Hippel-Lindau Syndrome

Sevda Dalar

Giresun Training and Research Hospital, Turkey.

Abstract

Paragangliomas are neuroendocrine neoplasms. They can be functional or non-functional. Although they can be seen in different localizations, they are rarely seen in the bladder. They may accompany hereditary syndromes. In this case report, a case of paraganglioma located in the bladder in a patient followed up with VHL syndrome is presented.

Keywords: Paraganglioma- bladder- von hippel-lindau syndrome

Asian Pac J Cancer Care, 8 (3), 655-657

Submission Date: 06/08/2023 Acceptance Date: 08/11/2023

Introduction

Paragangliomas are neuroendocrine neoplasms and they are derived neural crest arising from adrenal medulla (pheochromocytoma) and extra-adrenal paraganglia. They can be seen in many different localizations such as lower abdomen, retroperitoneum, pelvis. It is rarely observed in the bladder. It constitutes 0.06% of all bladder tumors [1]. They can be functional or non-functional. Functional ones may cause clinical symptoms related to catecholamine secretion [2]. Presentation at a young age, the presence of many tumor foci, and its extraadrenal location are mostly associated with the presence of germline mutations [3].

Von Hippel-Lindau Syndrome (VHL) syndrome is an autosomal dominant disease caused by pathogenic germline variants in the VHL tumor suppressor gene. Many different tumors can be seen in the urinary tract or central nervous system associated with VHL syndrome [4]. In this case report, a case of paraganglioma located in the bladder in a patient followed up with VHL syndrome is presented.

Case Report

An incidental lesion in the bladder was observed in a 53-year-old male patient followed up with VHL syndrome. In his history, he had 3 partial nephrectomy operations for renal cell carcinoma of his right and left kidney 4 years ago. In the ultrasound imaging, a hypoechoic, smooth-circumscribed solid nodular lesion

was observed on the anterior wall of the right inferior part, with a size of 9x16 mm, with prominent blood vessels and prominent lumen cambering. It did not spread directly into the lumen of the lesion (Figure 1A, 1B). Transurethral resection of the bladder mass was undertaken. In the bladder tissue, clusters of epithelioid cells with large eosinophilic cytoplasm and pigmentation in the cytoplasm were observed in the subepithelial area within the fibrovascular stroma. Positive staining with synaptophysin, chromogranin A, GATA3, panCK in tumor cells; positive staining with S100 was observed in sustentacular cells (Figure 1C, 1D). MART1, HMB45, smooth muscle actin, CK20, inhibin stained negative.

Ki-67 proliferative activity is 5%.

Paraganglioma, neuroendocrine tumor, pcoma, hemangioblastoma, urothelial carcinoma were included in the differential diagnosis. As a result of morphological and immunohistochemical findings, the case was found to be compatible with paraganglioma.

Discussion

Paragangliomas are non-epithelial tumors derived from paraganglion cells. The paraganglion system can be divided into as adrenal medulla and extra-adrenal paraganglion system. Extra-adrenal paraganglion system can be subdivided parasymphathetic and sympathetic.

Corresponding Author:

Dr. Sevda Dalar
Giresun Training and Research Hospital, Turkey.
Email: sevdaakyoll@gmail.com

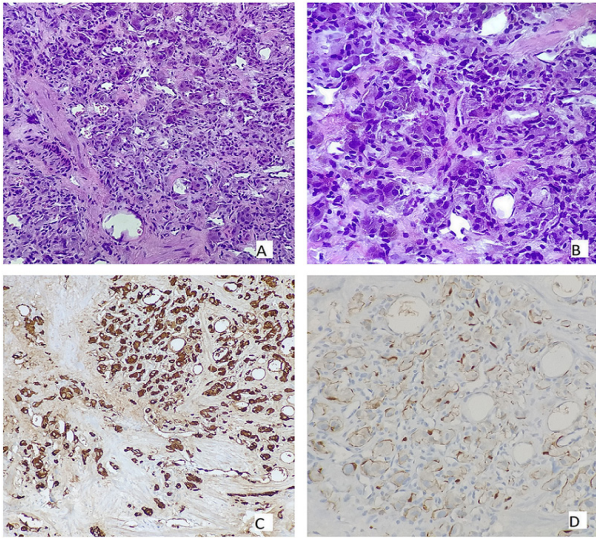


Figure 1. A. Paraganglioma Exhibiting a Nested Pattern and Surrounded by Sustentacular Cells (H&E; 200 \times). 1B, (H&E; 400 \times). 1C, On immunohistochemistry (DAB; 200 \times) neoplastic cells are positive for chromogranin A. 1D, On immunohistochemistry (DAB; 200 \times) sustentacular cells are positive for S100.

Parasympathetic paraganglia is primarily located in the head and neck region, sympathetic paraganglia is located along sympathetic nerve chains [5].

Most paragangliomas are sympathetic and functional. They can cause symptoms related to catecholamine release or mass effect. Symptoms such as palpitation, sweating, anxiety, paroxysmal hypertension may be seen due to adrenaline/noradrenaline release [6]. Our patient was nonsymptomatic.

Approximately 30-40% of paragangliomas in adults develop on the basis of hereditary disease [7]. They may be associated with various syndromes and familial conditions such as SDHx-related syndromes, VHL, neurofibromatosis type 1, multiple endocrine neoplasia type 2, hereditary leiomyomatosis and renal cell carcinoma, TMEM mutations, MAX mutations, EPAS1 mutations (Pazak-Zhuang syndrome), EGLN1/2 mutations, MDH2 mutations, KIF1B mutations, multiple endocrine neoplasia type 1, Carney triad. Susceptibility genes are grouped as pseudohypoxia-associated cluster (SDH, VHL, EGLN1, EGLN2, HIF2A), Krebs cycle genes (FH, IDH1, IDH2, MDH2), a kinase signaling clusters (RET, TMEM127, HRAS, NF1), WNT altered clusters (CSDE1 and MAML3) [8].

VHL is an autosomal dominant disease with a frequency of 2.8 per 100,000 [9]. VHL syndrome is caused by a pathogenic germline variant of the VHL tumor suppressor gene located on chromosome 3p25.3. Type 1 VHL syndrome has deletion and truncation mutation; type 2 VHL syndrome has missense mutation [10]. Central nervous system hemangioblastoma, clear cell renal cell carcinoma, pheochromocytoma, pancreatic endolymphatic sac tumor and pancreatic neuroendocrine tumor are associated with this syndrome. Our patient had a history of partial nephrectomy for clear cell renal cell carcinoma.

Paraganglioma exhibits a nested pattern causing the appearance of Zellballen. They are surrounded by sustentacular cells within the fibrovascular stroma. The nucleus is oval-round in shape and the cytoplasm is eosinophilic. Tumor cells show diffuse positive staining with neuroendocrine markers such as synaptophysin and chromogranin A. Sustentacular cells show positive immune reaction with S100 and SOX10.

Some paragangliomas may have clear cytoplasm and may be mistaken for prostate or kidney cancer. They require differential diagnosis with invasive urothelial carcinoma due to their localization in the lamina propria.

The hemangioblastoma seen in VHL syndrome is composed of neoplastic stromal cells arranged among numerous small vessels. Stromal cells have clear, foamy cytoplasm with lipid-containing vacuoles. These cells are differentiated from paragangliomas by positive staining with inhibin, S100, carbonic anhydrase IX.

Pecoma may be considered in the differential diagnosis as it consists of non-cohesive epithelioid cells with clear to eosinophilic granular cytoplasm. Tumor cells show positive staining for melanocytic markers (MART-1, HMB45, MiTF) and myogenic markers (SMA, desmin, kalsdesmon).

Neuroendocrine tumors are composed of monotonously regular cells with round or oval nuclei with salt and pepper chromatin and moderately eosinophilic granular cytoplasm, arranged in nests, trabecular or insular patterns. These tumors show positive immune reaction for neuroendocrine markers as well as keratins and transcription factors of specific site origin.

Scoring systems such as Pheochromocytoma of the Adrenal gland Scaled Score and Grading of Adrenal Pheochromocytoma and Paraganglioma exist to predict the likelihood of tumor metastasis. Malignant behavior is known to be defined on the basis of metastatic spread. Large tumor size, extra adrenal tumor location, catecholamine profile and SDHB mutation status are considered risk factors for metastatic behavior [11].

Paragangliomas are neuroendocrine neoplasms. They may accompany various hereditary syndromes. Differential diagnosis with many different tumor types is necessary to reach the correct diagnosis. Regular follow-up of patients with inherited syndromes allows early diagnosis and treatment of possible tumors.

References

1. Kappers MHV, Meiracker AH, Alwani RA, Kats E, Baggen MGA. Paraganglioma of the urinary bladder. *The Netherlands Journal of Medicine*. 2008 04;66(4):163-165.
2. Sherwani P, Anand R, Narula MK, Siddiqui AA, Aggarwal S. Concurrent nonfunctional paraganglioma of the retroperitoneum and urinary bladder: A case report with literature review. *The Indian Journal of Radiology & Imaging*. 2015;25(2):198-201. <https://doi.org/10.4103/0971-3026.155879>
3. Neumann HPH, Bausch B, McWhinney SR, Bender BU, Gimm O, Franke G, Schipper J, et al. Germ-line mutations in nonsyndromic pheochromocytoma. *The New England Journal of Medicine*. 2002 05 09;346(19):1459-1466. <https://doi.org/10.1056/NEJM020509346191459>

- doi.org/10.1056/NEJMoa020152
4. Maher ER, Neumann HP, Richard S. von Hippel-Lindau disease: a clinical and scientific review. *European journal of human genetics: EJHG*. 2011 06;19(6):617-623. <https://doi.org/10.1038/ejhg.2010.175>
 5. El-Naggar AK, Chan JKC, Grandis JR, Takata T, Slootweg PJ. WHO classification of head and neck tumours. IARC Lyon France. 2017..
 6. Lou Y, Fan L, Hou X, Dominiczak AF, Wang J, Staessen JA, Almustafa B, et al. Paroxysmal Hypertension Associated With Urination. *Hypertension (Dallas, Tex.: 1979)*. 2019 Nov;74(5):1068-1074. <https://doi.org/10.1161/HYPERTENSIONAHA.119.13140>
 7. Martins R, Bugalho MJ. Paragangliomas/Pheochromocytomas: clinically oriented genetic testing. *International Journal of Endocrinology*. 2014;2014:794187. <https://doi.org/10.1155/2014/794187>
 8. Fishbein L, Leshchiner I, Walter V, Danilova L, Robertson AG, Johnson AR, Lichtenberg TM, et al. Comprehensive Molecular Characterization of Pheochromocytoma and Paraganglioma. *Cancer Cell*. 2017 02 13;31(2):181-193. <https://doi.org/10.1016/j.ccell.2017.01.001>
 9. Gläsker S, Vergauwen E, Koch CA, Kutikov A, Vortmeyer AO. Von Hippel-Lindau Disease: Current Challenges and Future Prospects. *OncoTargets and Therapy*. 2020;13:5669-5690. <https://doi.org/10.2147/OTT.S190753>
 10. Albanyan S, Giles RH, Gimeno EM, Silver J, Murphy J, Faghfoury H, Morel CF, Machado J, Kim RH. Characterization of VHL promoter variants in patients suspected of Von Hippel-Lindau disease. *European Journal of Medical Genetics*. 2019 03;62(3):177-181. <https://doi.org/10.1016/j.ejmg.2018.07.006>
 11. Asa SL, Ezzat S, Mete O. The Diagnosis and Clinical Significance of Paragangliomas in Unusual Locations. *Journal of Clinical Medicine*. 2018 09 13;7(9):280. <https://doi.org/10.3390/jcm7090280>



This work is licensed under a Creative Commons Attribution-Non Commercial 4.0 International License.