

# Breast Carcinoma with Isolated Orbital Metastasis –A Rare Clinical Entity

Manish Sahni<sup>1</sup>, Harsha N Mehta<sup>2</sup>, Ravindra Gothwal<sup>2</sup>, Kamal Kishor Lakhera<sup>1</sup>, Suresh Singh<sup>1</sup>

<sup>1</sup>Department of Surgical Oncology, SMS Medical, College and Hospital, Jaipur, Rajasthan, India. <sup>2</sup>Department of Radiation Oncology Resident, SMS Medical College and Hospital, Jaipur, Rajasthan, India.

## Abstract

Breast cancer with isolated orbital metastasis is a rare clinical entity. We hereby present a rare case report of 35 year old premenopausal lady with known case of carcinoma breast right side (operated for right modified radical mastectomy in year 2017 with final histopathology of pT2N2M0, hormone receptor-positive and Her2-negative disease). She completed adjuvant 8 cycles of standard dose chemotherapy with 4 cycles of Cyclophosphamide, Adriamycin followed by 4 cycles of Paclitaxel followed by local Radiation therapy. She was initiated Tab. Tamoxifen 20 mg once daily and was continued same for 4 years when in July 2021, she complained of sudden decreased visual acuity and diplopia of right eye lasting from last 1 month. Ophthalmological examination confirmed the findings with decreased visual acuity of 6/36 of right eye while visual acuity of left eye was normal. CT scan of orbits revealed 28 × 18mm heterogeneous enhancing soft tissue mass in right orbital compartment, extrabulbar, occupying postero-superior quadrant inseparable from lateral rectus muscle with optic nerve effacement. PET-CT scan was performed which revealed no metastasis elsewhere in the body. She was offered surgical oophorectomy followed by switch to another hormonal therapy of aromatase inhibitors. She showed complete response to treatment and is now disease free from last 2 years.

**Keywords:** ER (Estrogen receptor)- PR (Progesterone receptor)- CT (Computer tomography)

*Asian Pac J Cancer Care*, 9 (2), 407-409

Submission Date: 11/06/2023      Acceptance Date: 02/14/2024

## Introduction

Breast cancer with isolated orbital metastasis is a rare clinical entity. Recently due to advancements in diagnostic imaging and treatment options, long-term survival of patients with metastatic disease with an increasing frequency of ocular involvement is diagnosed. It occurs in up to one-third of breast cancer patients [1, 2]. Bone metastases as a sole metastatic site in breast cancer portend a good prognosis, frequently seen in ER/PR (+) Her2/Neu (-) disease. A high index of suspicion is required for its urgent treatment as they are in close proximity to neighboring sensitive structures such as the spine or the eye.

### Case Report

A 35-year-old premenopausal lady with a known case of carcinoma breast right side (who underwent right

modified radical mastectomy in the year 2017 with a final histopathology of pT2N2M0, hormone receptor-positive and Her2-negative disease. She completed adjuvant 8 cycles of standard-dose chemotherapy with 4 cycles of Cyclophosphamide, Adriamycin followed by 4 cycles of Paclitaxel followed by local Radiation therapy. She was initiated on hormonal therapy with tablet Tamoxifen 20 mg once daily and continued the same for 4 years. In July 2021, she complained of a sudden decrease in visual acuity and diplopia of the right eye lasting for the last 1 month. Ophthalmologic examination confirmed the findings with decreased visual acuity of right eye with vision of 6/36. Left eye examination was normal. CT scan of orbits revealed a 28 × 18 mm heterogeneous enhancing soft tissue mass in the right orbital compartment, extrabulbar, occupying the postero-superior quadrant,

### Corresponding Author:

Dr. Manish Sahni

Mch Resident, Department of Surgical Oncology, SMS Medical, College and Hospital, Jaipur, Rajasthan, India.

Email: drmanish\_sahni@yahoo.com

inseparable from the lateral rectus muscle with optic nerve effacement. A PET-CT scan was performed, which revealed no metastasis elsewhere in the body (Figure 1). A CT guided orbital mass biopsy was performed by an interventional radiologist.

## Results

The final histopathology report of the right orbital mass was consistent with infiltrative carcinoma, with the immunohistochemical report showing tumor cells positive for estrogen/progesterone receptor. The final diagnosis of orbital metastasis from breast carcinoma was established. On further evaluation, her serum follicle-stimulating hormone /luteinizing hormone ratio was in premenopausal range, for which she was counseled for bilateral salpingo-oophorectomy. She underwent laparoscopic bilateral oophorectomy in August 2021 and was switched to another hormonal agent, an Aromatase inhibitors (Tablet Letrozole 2.5mg Once daily) since then. We offered her local intense modulated radiation therapy to the right orbit, but she refused owing to financial constraints. She was followed up every 3 months and showed improvement in eye symptoms since then. Her vision in the right eye gradually improved after initiation of therapy. Now, the patient has remained free from ocular symptoms for the last 12 months with improvement in vision and correction of diplopia. CT scan of the orbits revealed a significant reduction in tumor volume in orbital structures (Figure 2). PET-CT scan revealed non-FDG avid uptake over the right eye and elsewhere in the body.

## Discussion

Breast carcinoma is by far the most common primary site, accounting for the majority of orbital metastasis cases followed by lung, prostate, gastrointestinal, kidney, and skin cancers [1-5]. Usually, there is unilateral disease with predominant involvement of the lateral and superior quadrants of orbit [1]. Though the isolated orbital metastasis in breast cancer is a rarely diagnosed

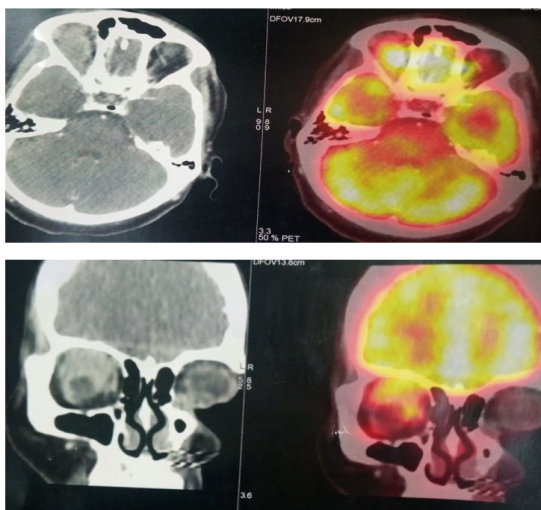


Figure 1. PET-CT Scan Showing Right Sided Orbital Metastasis-July 2021

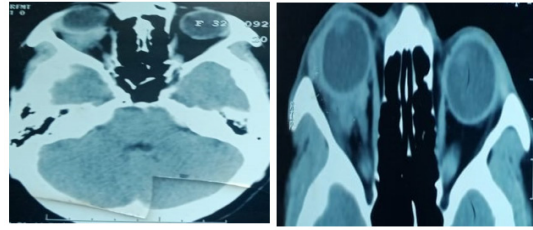


Figure 2. CT Scan Orbit Showing Good Response after Oophorectomy and Aromatase Inhibitors -April 2023

condition. High index of suspicion is required to diagnose it. Orbital metastasis usually presents in the background of disseminated disease with a long time interval of 4.5-6.5 years from the primary diagnosis of breast cancer [6]. Symptoms include diplopia (most common) followed by proptosis, visible mass, pain, ptosis, and blurred vision. Enophthalmos, if present, shows a distinctive sign of orbital infiltration by breast carcinoma [1, 5, 7, 8]. Though biopsy is required to get a definitive diagnosis of orbital mass but in patients with known metastatic cancer, it can be avoided if there is a past history of cancer and strong clinico-radiological suspicion for metastatic disease [1]. In our case report, CT-guided biopsy from the orbital mass was performed by an interventional radiologist to rule out if it was metastasis from breast carcinoma or a second primary cancer, even though she had a past history of breast carcinoma.

The treatment modality of both these entities would be different, so it would be prudent to take a biopsy from the suspected lesion as far as possible. Biopsy of the orbital mass was consistent with infiltrating carcinoma with immunohistochemical markers of estrogen and progesterone receptors positive for tumor cells. Immunohistochemical findings made a definitive diagnosis of orbital metastasis from breast carcinoma than a second primary in orbit. Treatment for orbital metastases is usually palliative as orbital metastases are considered to be part of disseminated disease. Surgical intervention is performed only for diagnostic purposes (biopsy) in patients with no previous history of cancer or as a palliative procedure in the form of tumor resection or enucleation for uncontrolled local symptoms [1, 9-12]. The main treatment modality remains radiotherapy, with high rates (60%-80%) of clinical improvement in local symptoms and vision. External-beam irradiation is the most common modality given with a total dose of 20-40 Gy delivered in fractions over 1-2 weeks [1, 5]. Stereotactic radiation therapy has recently evolved as an alternative modality in such anatomically constrained regions with high precision and a shorter duration of treatment, leading to a better quality of life [13]. But in our patient, the patient refused radiotherapy due to lack of family support and financial constraints. Also, the patient was having hormone receptor positive disease, she was offered bilateral salpingo-oophorectomy followed by initiation of Aromatase inhibitors. She is now disease free with improvement in vision from last 2 years and is on regular follow up with us.

Usually, the prognosis of patients with metastatic

orbital tumors is poor, with a median survival ranging from 22 to 31 months for breast cancer [1, 5]. But there are rare case reports which showed long-term survival of patient with breast carcinoma with orbital metastasis [14].

Our case report is unique as we could establish the diagnosis of isolated orbital metastasis with a proper biopsy. The standard role of induced menopause and endocrine therapy with aromatase inhibitors has definite role in improving the survival of patients with hormone receptor subset of disease. Our patient showed good response to treatment and is on regular follow up with frequent interval PET-CT scan showing good resolution of disease from last 2 years.

## References

- Ahmad SM, Esmali B. Metastatic tumors of the orbit and ocular adnexa. *Current Opinion in Ophthalmology*. 2007 09;18(5):405-413. <https://doi.org/10.1097/ICU.0b013e3282c5077c>
- Wickremasinghe S, Dansingani KK, Tranos P, Liyanage S, Jones A, Davey C. Ocular presentations of breast cancer. *Acta Ophthalmologica Scandinavica*. 2007 03;85(2):133-142. <https://doi.org/10.1111/j.1600-0420.2006.00737.x>
- Fahmy P, Heegaard S, Jensen OA, Prause JU. Metastases in the ophthalmic region in Denmark 1969-98. A histopathological study. *Acta Ophthalmologica Scandinavica*. 2003 02;81(1):47-50. <https://doi.org/10.1034/j.1600-0420.2003.00018.x>
- Holland D, Maune S, Kovács G, Behrendt S. Metastatic tumors of the orbit: a retrospective study. *Orbit (Amsterdam, Netherlands)*. 2003 03;22(1):15-24. <https://doi.org/10.1076/orbi.22.1.15.14007>
- Shields JA, Shields CL, Brotman HK, Carvalho C, Perez N, Eagle RC. Cancer metastatic to the orbit: the 2000 Robert M. Curts Lecture. *Ophthalmic Plastic and Reconstructive Surgery*. 2001 09;17(5):346-354. <https://doi.org/10.1097/00002341-200109000-00009>
- Milman T, Pliner L, Langer PD. Breast carcinoma metastatic to the orbit: an unusually late presentation. *Ophthalmic plastic and reconstructive surgery*. 2008 Dec;24(6). <https://doi.org/10.1097/IOP.0b013e31818b6adc>
- Chang BYP, Cunniffe G, Hutchinson C. Enophthalmos associated with primary breast carcinoma. *Orbit (Amsterdam, Netherlands)*. 2002 Dec;21(4):307-310. <https://doi.org/10.1076/orbi.21.4.307.8559>
- De Potter P, Disneur D, Levecq L, Snyers B. [Ocular manifestations of cancer]. *Journal Francais D'ophtalmologie*. 2002 02;25(2):194-202.
- Dieing A, Schulz C, Schmid P, Roever AC, Lehenbauer-Dehm S, Jehn C, Flath B, Possinger K. Orbital metastases in breast cancer: report of two cases and review of the literature. *Journal of Cancer Research and Clinical Oncology*. 2004 Dec;130(12):745-748. <https://doi.org/10.1007/s00432-004-0606-3>
- Kouvaris JR, Gkongkou PV, Papadimitriou CA, Papacharalampous XN, Antypas CE, Balafouta MJ, Vlahos LJ. Bilateral metastases to extraocular muscles from lobular breast carcinoma. *Onkologie*. 2008 07;31(7):387-389. <https://doi.org/10.1159/000129689>
- Wong Z, Phillips SJ, Ellis MJ. Dramatic response of choroidal metastases from breast cancer to a combination of trastuzumab and vinorelbine. *The Breast Journal*. 2004;10(1):54-56. <https://doi.org/10.1111/j.1524-4741.2004.09614.x>
- Talwar V, Vaid AK, Doval DC, Bhatia K, Jena A, Anand AK. Isolated intraorbital metastasis in breast carcinoma. *The Journal of the Association of Physicians of India*. 2007 06;55:451-452.
- Bellmann C, Fuss M, Holz FG, Debus J, Rohrschneider K, Völcker HE, Wannemacher M. Stereotactic radiation therapy for malignant choroidal tumors: preliminary, short-term results. *Ophthalmology*. 2000 02;107(2):358-365. [https://doi.org/10.1016/s0161-6420\(99\)00081-0](https://doi.org/10.1016/s0161-6420(99)00081-0)
- González F, López-Couto C. [Orbital metastases. A report of four cases and a review of the literature]. *Archivos De La Sociedad Espanola De Oftalmologia*. 2006 08;81(8):451-462. <https://doi.org/10.4321/s0365-66912006000800006>



This work is licensed under a Creative Commons Attribution-Non Commercial 4.0 International License.