

# Outcome of Patients with Early Glottic Laryngeal Carcinoma Treated with Radical Radiotherapy

Joneetha Jones<sup>1</sup>, Vinin N V<sup>1</sup>, Shalin Sebastian<sup>1</sup>, Geetha Muttath<sup>1</sup>, Arun P Narendran<sup>1</sup>, Nabeel Yahiya<sup>1</sup>, Bindu Anil<sup>2</sup>

<sup>1</sup>Department of Radiation Oncology, Malabar Cancer Centre, India. <sup>2</sup>Department of Biostatistics, Malabar Cancer Centre, India.

## Abstract

**Introduction:** Glottic cancer is the most common laryngeal cancer and it has the most favorable prognosis, mainly if diagnosed early. Ideally, early glottic cancer (T1–T2 N0) should be managed with a single modality either microsurgery or definitive Radiotherapy. The local control rate with definitive radiotherapy is approximately 83–95% for T1 and 70–80% for T2 lesions. This study intends to find out the treatment outcome in early glottic cancer treated with radical radiation treatment from 1<sup>st</sup> January 2014 to 31<sup>st</sup> December 2019 at our center. **Methods:** This was a retrospective analysis of medical records and radiation charts of all patients of early stage glottis cancer who underwent radiation treatment from 1<sup>st</sup> January 2014 to 31<sup>st</sup> December 2019 at our centre. The statistical analysis was done using SPSS version 20.0. Continuous variables such as age was summarized in terms of either mean  $\pm$  Standard Deviation or median (inter quartile range) depending on the statistical distribution of data. Categorical variables were expressed in terms of frequency and percentage. Survival analysis was done using Kaplan Meier curves. **Results:** A total of 91 patients underwent radical radiation for early glottic carcinoma at our centre. The median age was 63 years (42–85 years). Out of them 94% were males and 6% were females. 78% of patients had stage I disease and 22% had stage II disease. 52% of patients had co morbidities and 48% did not have any comorbidity. All cases had Squamous cell carcinoma histology. 59% of patients had anterior commissure involvement. 12 out of 91 (13%) patients developed local recurrence on follow up. The five year disease free survival was 84.3%. The five year overall survival was 87.7%. There was a statistically significant difference in survival between stage I and stage II. **Conclusion:** For T1–T2 glottic carcinomas, definitive RT can provide a good term local control and survival with the preservation of the normal structure and function of larynx.

**Keywords:** Neuroendocrine carcinoma- small cell carcinoma- bladder cancer- immunohistochemistry- organ preservation

*Asian Pac J Cancer Care*, 9 (3), 475-480

Submission Date: 02/07/2024

Acceptance Date: 05/22/2024

## Introduction

Larynx cancer is the most common cancer of the head and neck with the exception of the skin and it accounts for 2% of all cancer diagnosed [1, 2]. Since larynx plays important roles in phonation, respiration and deglutition, the treatment goal of laryngeal cancer is not only to control the disease but also to preserve the functional larynx. Radiotherapy provides better functional status compared with partial surgery due to the capability of normal tissue protection. Glottic carcinoma typically presents early, and unlike many other Head and Neck malignancies, lack of lymphatic drainage in the glottis mucosa carries lower risk of lymph node involvement. Early glottic

carcinoma (EGC) is defined as tumor confined to one (T1a), both vocal cords (T1b), or tumor that extends to supraglottic or subglottis with minimal functional impairment of vocal cords (T2). It includes T1/T2 node negative disease. The treatment modalities available for early glottic cancers include transoral laser excision, open partial laryngectomy or radical radiation treatment [3, 4]. The management of early glottic carcinomas is often determined by an anticipated general medical condition, patient's wishes, functional outcome, preferences and expertise of the attending clinicians and tumor factors [5, 6]. Five years of local control rates are 85–94% for

## Corresponding Author:

Dr. Vinin N V

Department of Radiation Oncology, Malabar Cancer Centre, India.

Email: joneetha14@gmail.com

T1 glottic cancers and 70–85% for T2 with radical RT in the literature [7-10]. This study aims to evaluate the clinic pathological characteristics, the treatment outcomes including disease-free survival (DFS), and overall survival (OS), in early glottis cancer patients treated with radical radiation treatment at our institution.

## Materials and Methods

The study was conducted in the Department of radiation oncology Malabar Cancer Centre. This was a retrospective analysis of medical records and radiation charts of all patients of early stage glottis cancer who underwent radiation treatment from 1<sup>st</sup> January 2014 to 31<sup>st</sup> December 2019 at our center. Demographic details like age, sex, stage, histology and radiation details like the dose prescribed and radiation technique used and grade 3 or 4 toxicities were recorded from the medical records. Also the date of registration, date of RT start, date of completion, date of recurrence, date of last follow up, date of death, cause of death if known was collected from case records.

All cases were discussed in the multi specialty tumor board comprising the surgical, medical, radiation oncologists, radiologist and pathologists. The decision of selecting a patient for surgery or radiation was made in the tumor board. For radiation treatment planning all patients were immobilized with custom made thermoplastic shells. Planning CT scans were taken with IV contrast if renal function was normal and a slice thickness of 2.5mm from vertex to sternum. Images were then exported on to the treatment planning system and contouring was done as per the RTOG (Radiation Therapy Oncology Group) guidelines. All patients were treated with conformal techniques in Varian Clinac ix or Versa HD medical linear accelerators. Treatment consisted of 3D conformal 6 MV photon RT delivered with a linear accelerator, employing a parallel-opposed latero-lateral beam arrangement using wedges and multi-leaf collimator to spare normal tissues. The dosage schedules employed were 70 Gy in 35 fractions or 66 Gy in 33 fractions.

Disease Free Survival (DFS) was defined as the time from completion of radiation to loco regional failure, distant failure or death resulting from any disease, whichever occurred first.

Overall (OS) was calculated from the time from diagnosis to death resulting from any cause or last follow up date.

### Statistical Analysis

The statistical analysis was done using SPSS version 20.0. Continuous variables such as age was summarized in terms of either mean  $\pm$  Standard Deviation or median (Interquartile range) depending on the statistical distribution of data. Categorical variables were expressed in terms of frequency and percentage. Survival analysis was done using Kaplan Meier curves.

## Results

A total of 91 patients underwent radical radiation for early glottis carcinoma at our center. The median age was 63 years (42-85 years). Out of them 94% were males and 6% were females. 78% of patients had stage I disease and 22% had stage II disease. 52% of patients had comorbidities and 48% did not have any comorbidity. All cases had Squamous cell carcinoma histology. Majority of them were moderately differentiated followed by well differentiated histology. 59% of patients had anterior commissure involvement. 69 patients were treated with 70 Gy in 35 fractions, 21 patients received 66 Gy in 33 fractions and 1 patient had 5250cGy in 15 fractions (Table 1).

### Local Recurrence Rate

12 out of 91 (13%) patients developed local recurrence on follow up. Among them one patient had both local and regional nodal recurrence. One patient developed nodal recurrence in the absence of local recurrence. Nodal recurrence was seen in 2% of patients.

### Disease Free Survival

The median duration of follow up was 51 months. The 5 year disease free survival was 84.3% (Figure 1).

DFS was analyzed for stage I and Stage II disease. For stage I disease the 5 year DFS was 88.8% and for stage II

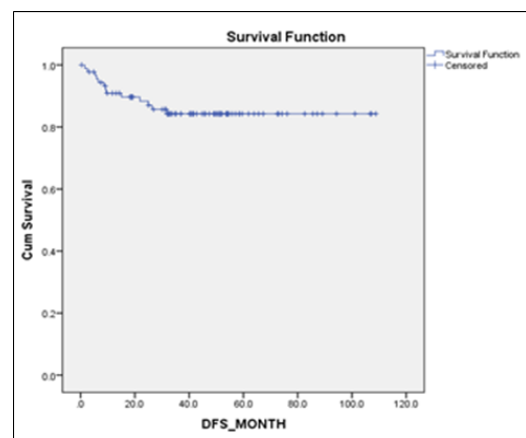


Figure 1. Showing Disease Free Survival

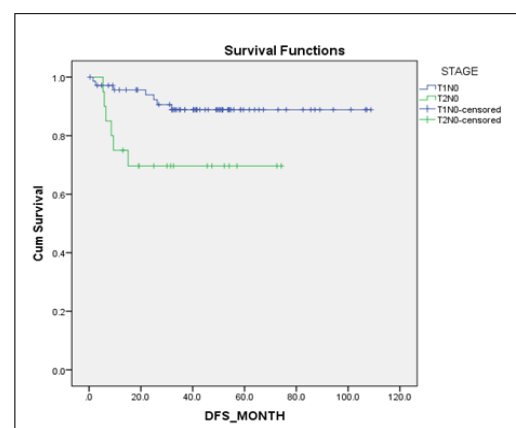


Figure 2. Showing DFS for Stage I and Stage II Disease

Table 1. Baseline Characteristics

Sex		%
Sex	Male	94
	Female	6
ECOG Performance Status	0/I	94
	II	6
Comorbidity	Yes	52
	No	48
Histology	WD SCC	31
	MD SCC	32
	PD SCC	4
	Differentiation	
	Unknown	29
Stage	CIS	4
	Stage I	78
	Stage II	22
Anterior Commissure Involvement	Yes	59
	No	41
Dose of Radiation	70GY/35#	76
	66GY/33#	23
	52.5GY/15#	1

disease the 5 year DFS was 69.6%. There was statistically significant difference in DFS between the stages (p value 0.015) (Figure 2).

#### Overall Survival

The five year overall survival was 87.7% (Figure 3).

For stage I disease the 5 year overall survival was 92.5% and for stage II disease the 5 year overall survival was 69.7%. There was a statistical significant difference between the OS based on stage (p value 0.012) (Figure 4).

#### Factors Affecting Survival

There was no statistically significant association between gender, performance status, comorbidity, anterior commissure involvement, histology or dose of radiation treatment and survival (Figure 5).

#### Acute Toxicities

The most common grade 3 toxicity occurred was dermatitis which was seen in 29% of patients.

#### Second Primary Malignancies

6 out of 91 Patients (6%) developed second malignancies on follow up. 3 patients developed Carcinoma Lung, one Patient had Metastatic Carcinoma Stomach, one had Carcinoma Rectum and one developed

Metastatic Carcinoma Prostate on follow up.

## Discussion

Early-stage glottic laryngeal carcinomas can be cured by radical RT or local surgical excision [11]. The treatment decision depends on tumor characteristics like tumor location, single or bilateral vocal cord, and anterior commissure involvement and patient preferences. There is no difference between the methods in terms of local control when appropriate patients are selected. Radiotherapy generally has the advantage of providing better voice quality [12, 13].

The median age of our study population was 62 years. In a study conducted by Chera et al [14] the median age was 63 years. In that same study 93% were males and 7% were females and in our study 94% were males and 6% were females. In our study 78% were stage I disease where as 22% were stage II. In a study by Cetinayak et al [15] 83% belonged to stage I and 17% had stage II disease whereas in the study by Chera et al [14] 56% had stage I disease and 44% had stage II disease. Anterior commissure involvement was seen in 59% of our cases where as it was seen only in 35% of cases in the study conducted by Cetinayak et al [15].

In the study by Cetinayak et al [15] 5% patients were treated with the conventional technique, 41.8% cases were treated with 3DCRT, and 14.7% with VMAT. The median dose of RT was 66 (50–70) Gy. In our study all patients were treated with 3DCRT. 76% received 70 Gy in 35 fractions, 23% had 66 Gy in 33 fractions and one patient received 52.5 Gy in 15 fractions. Hypofractionated RT regimens became more common after a randomized trial from Japan demonstrated better local control rates [16]. In our study only one patient had radiation with hypofractionated regimen.

With respect to patterns of failure, local recurrences are commonly seen at or near the primary tumor subsite. Ermiş et al. [17] evaluated the recurrence patterns of early stage glottic carcinoma treated with hypofractionated RT. They found that 11% of patients recurred at or near the primary tumor subsite. Only 2% of patients had regional lymphatic metastasis alone. Lim et al [18] analyzed the recurrence patterns and found that 15% recurrences

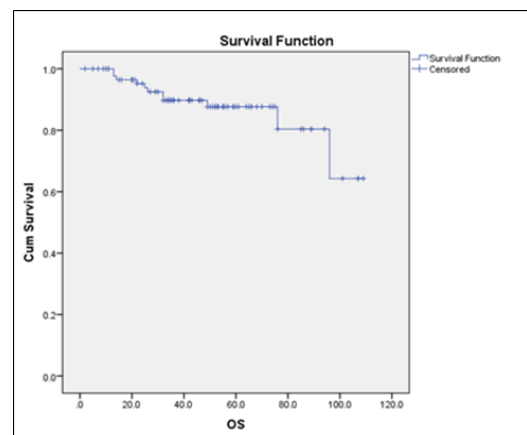


Figure 3. Showing Overall Survival

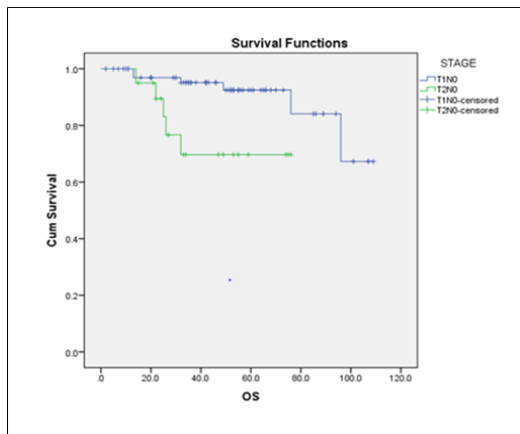


Figure 4. Showing Overall Survival for Stage I and Stage II Disease.

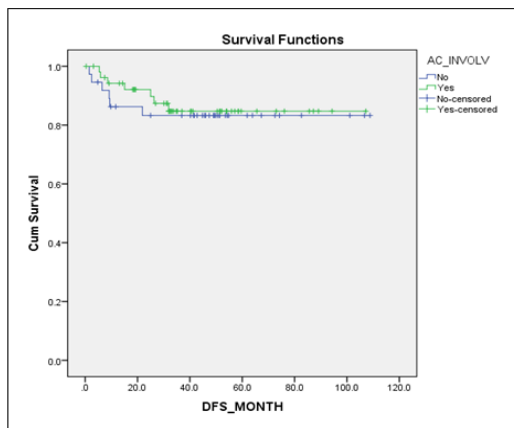


Figure 5. Showing Disease Free Survival Based on Anterior Commissure Involvement

were at or near the primary tumor subsite. The regional recurrences were seen only in 8% patients in their report. In our study, we found that 12 (13%) patients had isolated local recurrences without any lymphatic metastasis and only 2 % patients had regional lymphatic metastasis. Our results were similar to current literature.

Johansen et al [19] evaluated 861 glottic laryngeal carcinoma cases retrospectively and reported 5 years of disease-specific survival rates for T1a, T1b, and T2 tumors to be 95%, 93%, and 83%, respectively. Chera et al [14] evaluated retrospectively 585 patients with T1N0, T2N0 glottic larynx carcinoma treated by RT at Florida University. In this study, 5 years of local control rates were reported as 94% for T1a; 93% for T1b; 80% for T2a, and 70% for T2b. In our study the 5 year disease free survival was found to be 84.3%. For T1 lesions the 5 year disease free survival was 88.8% and for T2 lesions the 5 year survival was 69.6% which was lower when compared to literature data. This might be due to the lower number of patients in our study. Also in our study 22% had stage II disease. In a study by Thariat et al [20] the Disease-free survival was 68% for the whole group, 77% for T1a, 51% for T1b, 58% for T2 respectively.

In a study conducted by Ahamed Tali et al [21] in India, 5 years of overall survival and disease free survival for T1a, T1b, T2 were found to be 91%, 80%, 62%. Thariat

et al [20]. evaluated 155 patients with T1 and T2 glottic carcinomas. Overall survival was 75% for the whole group, 85% for T1a, 72% for T1b, 59% for T2. The five year overall survival for the whole group in our study was 87.7%. For stage I disease the five year overall survival was 92.5% and for stage II disease it was 69.7%.

In the study by Cetinayak et al [15], Stage and anterior commissure involvement were found to be significant in overall survival and disease-free survival. In our study there was no statistically significant association between gender, performance status, comorbidity, anterior commissure involvement. There was a statistically significant difference in DFS between the stages (p value 0.015). Also there was a statistical significant difference between the OS based on stage (p value 0.012). In a study conducted by Nur et al [22], T classification proved to be the only independent prognostic factor affecting the local control. In the study conducted by Jin et al [23] Bulky tumor, anterior commissure involvement, and decreasing hemoglobin were negative prognostic factors for local control.

In our cohort, treatment was well-tolerated, with the majority of patients experiencing grade 1 or 2 toxicities either dermatitis or mucositis. Other toxicities recorded were odynophagia and cough. No patients underwent tracheostomy during radiation. Late sequelae were not recorded. The toxicity profile was in agreement with those of previous reports. In a study by Kim et al [24] majority of patients had radiation mucositis and dermatitis presenting from 2 weeks of RT start, and complained of throat pain on swallowing and voice change. These acute side effects were grade 2 or lower, and was controlled with symptomatic management.

6% of our patients developed second malignant neoplasms on follow up out of which 50% had malignancy in the upper aero digestive tract (carcinoma lung). Rest of them had carcinoma stomach, carcinoma rectum and carcinoma prostate. In a study conducted by Fujita et al [25] in early glottic cancer treated with radiation the incidence of second malignant neoplasia was 22%. In a study conducted by Holland et al [26] the incidence of second primary malignancy was 28%.

Levendag et al [27]. showed that IMRT had a significant dosimetric advantage regarding organ at risk doses and they suggested that ipsilateral vocal cord irradiation with newer technologies could be examined, especially for T1 glottic carcinomas. But when we analyze the recurrence rates of trials, we should treat the whole laryngeal structure with required radiation doses. All our patients were irradiated with three dimensional conformal RT techniques including the entire larynx in the treatment portal. In a retrospective analysis conducted by Niema et al [28] in patients with early-stage glottic cancer, retrospective data suggests local and regional control are similar for patients treated with IMRT and CRT. The role of IMRT in early stage carcinoma larynx needs to be validated in large prospective studies.

In conclusion, it can be concluded that the patients with early-stage glottic laryngeal carcinoma, local control, overall, disease-free survival rates that we have

achieved with radical radiotherapy are comparable with the literature with less frequent side effects. By the early detection of failures with multidisciplinary follow-ups, effective voice protective salvage treatments can be applied.

## Acknowledgments

### Statement of Transparency and Principals:

- Author declares no conflict of interest
- Study was approved by Research Ethic Committee of author affiliated Institute.
- Study's data is available upon a reasonable request.
- All authors have contributed to implementation of this research.

## References

1. National Center for Biotechnology Information, U.S. National Library of Medicine 8600 Rockville Pike, Bethesda MD, 20894 USA. *Journal List Acta Otorhinolaryngol Ital* v.30(4); 2010 Aug PMC3008153.
2. Hansen E, Roach M. Larynx and hypopharynx cancer. In: *Handbook of evidence-based radiation oncology*. second ed. New York Heidelberg Dordrecht London: Springer; 2010.
3. Petrakos I, Kontzoglou K, Nikolopoulos TP, Papadopoulos O, Kostakis A. Glottic and supraglottic laryngeal cancer: epidemiology, treatment patterns and survival in 164 patients. *Journal of B.U.ON.: official journal of the Balkan Union of Oncology*. 2012;17(4):700-705.
4. Guimarães AV, Deditis RA, Matos LL, Aires FT, Cernea CR. Comparison between transoral laser surgery and radiotherapy in the treatment of early glottic cancer: A systematic review and meta-analysis. *Scientific Reports*. 2018 08 09;8(1):11900. <https://doi.org/10.1038/s41598-018-30218-x>
5. Mendenhall WM, Werning JW, Hinerman RW, Amdur RJ, Villaret DB. Management of T1-T2 glottic carcinomas. *Cancer*. 2004 05 01;100(9):1786-1792. <https://doi.org/10.1002/cncr.20181>
6. Ferreira N, Netto E, Fonseca L, Fonseca J, Esteves S, Labareda M, Mota A, Pocinho R, Magalhães M, Santos F. Surgery versus radiotherapy: Long term outcomes of T1 glottic cancer. *Reports of Practical Oncology and Radiotherapy: Journal of Great Poland Cancer Center in Poznan and Polish Society of Radiation Oncology*. 2020;25(6):860-866. <https://doi.org/10.1016/j.rpor.2020.08.007>
7. Al-Mamgani A, Rooij PH, Woutersen DP, Mehilal R, Tans L, Monserez D, Baatenburg de Jong RJ. Radiotherapy for T1-2N0 glottic cancer: a multivariate analysis of predictive factors for the long-term outcome in 1050 patients and a prospective assessment of quality of life and voice handicap index in a subset of 233 patients. *Clinical otolaryngology: official journal of ENT-UK ; official journal of Netherlands Society for Oto-Rhino-Laryngology & Cervico-Facial Surgery*. 2013 08;38(4):306-312. <https://doi.org/10.1111/coa.12139>
8. Khan MK, Koyfman SA, Hunter GK, Reddy CA, Saxton JP. Definitive radiotherapy for early (T1-T2) glottic squamous cell carcinoma: a 20 year Cleveland Clinic experience. *Radiation Oncology (London, England)*. 2012 Nov 19;7:193. <https://doi.org/10.1186/1748-717X-7-193>
9. Canis M, Ihler F, Martin A, Matthias C, Steiner W. Transoral laser microsurgery for T1a glottic cancer: review of 404 cases. *Head & Neck*. 2015 06;37(6):889-895. <https://doi.org/10.1002/hed.23688>
10. Cacicedo J, Casquero F, Hoyo O, Gomez-Iturriaga A, Martinez-Indart L, Lopez JL, Bilbao P. Definitive radiotherapy for T1 glottic squamous cell carcinoma: a 15-year Cruces University Hospital experience. *Clinical & Translational Oncology: Official Publication of the Federation of Spanish Oncology Societies and of the National Cancer Institute of Mexico*. 2013 Nov;15(11):925-931. <https://doi.org/10.1007/s12094-013-1025-1>
11. Hartl DM. Evidence-based practice: management of glottic cancer. *Otolaryngologic Clinics of North America*. 2012 Oct;45(5):1143-1161. <https://doi.org/10.1016/j.otc.2012.06.014>
12. Greulich MT, Parker NP, Lee P, Merati AL, Misono S. Voice outcomes following radiation versus laser microsurgery for T1 glottic carcinoma: systematic review and meta-analysis. *Otolaryngology--Head and Neck Surgery: Official Journal of American Academy of Otolaryngology-Head and Neck Surgery*. 2015 05;152(5):811-819. <https://doi.org/10.1177/0194599815577103>
13. Gioacchini FM, Tulli M, Kaleci S, Bondi S, Bussi M, Re M. Therapeutic modalities and oncologic outcomes in the treatment of T1b glottic squamous cell carcinoma: a systematic review. *European archives of oto-rhinolaryngology: official journal of the European Federation of Oto-Rhino-Laryngological Societies (EUFOS): affiliated with the German Society for Oto-Rhino-Laryngology - Head and Neck Surgery*. 2017 Dec;274(12):4091-4102. <https://doi.org/10.1007/s00405-017-4736-z>
14. Chera BS, Amdur RJ, Morris CG, Kirwan JM, Mendenhall WM. T1N0 to T2N0 squamous cell carcinoma of the glottic larynx treated with definitive radiotherapy. *International Journal of Radiation Oncology, Biology, Physics*. 2010 Oct 01;78(2):461-466. <https://doi.org/10.1016/j.ijrobp.2009.08.066>
15. Cetinayak O, Dogan E, Kuru A, Akturk N, Aydin B, Umay C, Er I, Akman F. Outcome of Early-Stage Glottic Laryngeal Carcinoma Patients Treated with Radical Radiotherapy Using Different Techniques. *Journal of Oncology*. 2019;2019:8640549. <https://doi.org/10.1155/2019/8640549>
16. Yamazaki H, Nishiyama K, Tanaka E, Koizumi M, Chatani M. Radiotherapy for early glottic carcinoma (T1N0M0): results of prospective randomized study of radiation fraction size and overall treatment time. *International Journal of Radiation Oncology, Biology, Physics*. 2006 01 01;64(1):77-82. <https://doi.org/10.1016/j.ijrobp.2005.06.014>
17. Ermiş E, Teo M, Dyker KE, Fosker C, Sen M, Prestwich RJ. Definitive hypofractionated radiotherapy for early glottic carcinoma: experience of 55Gy in 20 fractions. *Radiation Oncology (London, England)*. 2015 09 23;10:203. <https://doi.org/10.1186/s13014-015-0505-6>
18. Lim YJ, Wu H, Kwon T, Hah JH, Sung M, Kim KH, Park CI. Long-Term Outcome of Definitive Radiotherapy for Early Glottic Cancer: Prognostic Factors and Patterns of Local Failure. *Cancer Research and Treatment*. 2015 Oct;47(4):862-870. <https://doi.org/10.4143/crt.2014.203>
19. Johansen LV, Grau C, Overgaard J. Glottic carcinoma--patterns of failure and salvage treatment after curative radiotherapy in 861 consecutive patients. *Radiation Oncology: Journal of the European Society for Therapeutic Radiology and Oncology*. 2002 06;63(3):257-267. [https://doi.org/10.1016/s0167-8140\(02\)00118-4](https://doi.org/10.1016/s0167-8140(02)00118-4)
20. Thariat J, Bruchon Y, Bonnetain F, Barillot I, Truc G, Peignaux K, Horiot JC, Maingon P. Conservative treatment of early glottic carcinomas with exclusive radiotherapy.

Cancer Radiotherapie: Journal De La Societe Francaise De Radiotherapie Oncologique. 2004 Oct;8(5):288-296. <https://doi.org/10.1016/j.canrad.2004.08.003>

21. Tali T, Amin F, Dar J, Sofi S, Sofi MA, Khan N, Dar N. Treatment Outcome of Early-stage Laryngeal Carcinoma Treated with Radical Radiotherapy Using Different Techniques: A Retrospective Study. *Asian Pacific Journal of Cancer Care*. 2023 05 31;8:269-273. <https://doi.org/10.31557/apjcc.2023.8.2.269-273>
22. Nur DA, Oguz C, Kemal ET, Ferhat E, Sülen S, Emel A, Münir K, Ann CSR, Mehmet S. Prognostic factors in early glottic carcinoma implications for treatment. *Tumori*. 2005;91(2):182-187. <https://doi.org/10.1177/030089160509100215>
23. Jin J, Liao Z, Gao L, Huang X, Xu G. Analysis of prognostic factors for T(1)N(0)M(0) glottic cancer treated with definitive radiotherapy alone: experience of the cancer hospital of Peking Union Medical College and the Chinese Academy Of Medical Sciences. *International Journal of Radiation Oncology, Biology, Physics*. 2002 Oct 01;54(2):471-478. [https://doi.org/10.1016/s0360-3016\(02\)02920-6](https://doi.org/10.1016/s0360-3016(02)02920-6)
24. Kim RY, Marks ME, Salter MM. Early-stage glottic cancer: importance of dose fractionation in radiation therapy. *Radiology*. 1992 01;182(1):273-275. <https://doi.org/10.1148/radiology.182.1.1727295>
25. Fujita M, Rudoltz MS, Canady DJ, Patel P, Machtay M, Pittard MQ, Mohiuddin M, Regine WF. Second malignant neoplasia in patients with T1 glottic cancer treated with radiation. *The Laryngoscope*. 1998 Dec;108(12):1853-1855. <https://doi.org/10.1097/00005537-199812000-00016>
26. Holland JM, Arsanjani A, Liem BJ, Hoffelt SC, Cohen JI, Stevens KR. Second malignancies in early stage laryngeal carcinoma patients treated with radiotherapy. *The Journal of Laryngology and Otology*. 2002 03;116(3):190-193. <https://doi.org/10.1258/0022215021910500>
27. Levendag PC, Teguh DN, Keskin-Cambay F, Al-Mamgani A, Rooij P, Astreimidou E, Kwa SLS, Heijmen B, Monserez DA, Osman SOS. Single vocal cord irradiation: a competitive treatment strategy in early glottic cancer. *Radiotherapy and Oncology: Journal of the European Society for Therapeutic Radiology and Oncology*. 2011 Dec;101(3):415-419. <https://doi.org/10.1016/j.radonc.2011.05.026>
28. Razavian NB, D'Agostino RB, Shenker RF, Hughes RT. Intensity-Modulated Radiation Therapy for Early-Stage Squamous Cell Carcinoma of the Glottic Larynx: A Systematic Review and Meta-Analysis. *International Journal of Radiation Oncology, Biology, Physics*. 2023 Nov 01;117(3):652-663. <https://doi.org/10.1016/j.ijrobp.2023.04.035>



This work is licensed under a Creative Commons Attribution-Non Commercial 4.0 International License.