

# Back Pain as Presenting Main Symptom in Incidental Finding of Lung Nodule EGFR Mutation: A Case Report

Haryati Haryati<sup>1</sup>, Ika Kustiyah Oktaviyanti<sup>2</sup>, Muhammad Iqbal<sup>3</sup>

<sup>1</sup>Department of Pulmonology and Respiratory Medicine, Faculty of Medicine, Lambung Mangkurat University, Banjarmasin, South Kalimantan, Indonesia. <sup>2</sup>Department of Pathology Anatomy, Faculty of Medicine, Lambung Mangkurat University, Banjarmasin, South Kalimantan, Indonesia. <sup>3</sup>Department of Orthopedics and Traumatology Clinics, Faculty of Medicine, Lambung Mangkurat University, Banjarmasin, South Kalimantan, Indonesia.

## Abstract

Lung cancer can spread to the bones, and when it affects the spine, it can be initially misdiagnosed as a common musculoskeletal cause of back pain. We present the case of a formerly healthy 59-year-old male smoker with no pulmonary symptoms who presented with a two-month history of back pain before developing spinal cord compression syndrome. It was later discovered that he suffered from vertebra metastasis T7 level with stenosis canalis spinal due to metastasis adenocarcinoma solitary pulmonary nodule. The patient also presented a positive epidermal growth factor receptor (EGFR) mutation. Laminectomy and posterior stabilization with tyrosine kinase inhibitor therapy are performed on the patient. It underscores the significance of conducting lung cancer screenings and the criticality of vigilantly observing for warning signs of back pain, such as progressive worsening back pain symptoms despite treatment.

**Keywords:** Back pain- Bone metastasis- Lung Nodule- Adenocarcinoma- EGFR mutation

*Asian Pac J Cancer Care*, 9 (3), 609-611

Submission Date: 03/11/2024    Acceptance Date: 06/01/2024

## Introduction

Lung cancer is the main cause of cancer fatalities in men and women [1]. The majority of non-small cell lung cancer (NSCLC) patients, specifically over 40%, are classified as adenocarcinoma [2, 3]. The majority of lung cancer patients have symptoms, while others are asymptomatic. A review of 2293 NSCLC patients found that 54.7% reported a cough and 45.3% had dyspnea, the two most prevalent symptoms [4]. However, extrathoracic spread symptoms affect about one-third of individuals [2]. Bone metastasis is prevalent in NSCLCs, especially in the vertebral column. In 30–40% of advanced illness patients, vertebral metastasis occurs [5, 6]. Cord compression occurs in 5% of bone metastasis cases across all cancer types. Lung cancer causes 15% of metastatic cord compression, second only to breast cancer [7]. The prognostic of patients with lung cancer metastasis to the spine is poor, with only a 31.6% one-year survival rate. Thus, early cancer diagnosis and molecular assays like epidermal growth factor

receptor (EGFR) are needed for clinical management [8]. This report presents a case study of a patient with no respiratory symptoms enduring persistent back pain. Later on, he experienced cord compression syndrome, which resulted in the identification of metastatic adenocarcinoma with a positive EGFR mutation. The surgical intervention followed by the EGFR tyrosine kinase inhibitor improved the patient's quality of life.

## Case Report

A 59-year-old man with no prior medical history of illness reported experiencing a two-monthly history of persistent back pain, which he rated as a seven out of ten on the numeric pain rating scale, and loss of appetite and weight loss of about 5 kg. The patient was referred to our hospital because the symptoms were worsening. He complained of constipation, numbness, and inability to walk because of limb weakness. The patient

## Corresponding Author:

Dr. Haryati Haryati

Department of Pulmonology and Respiratory Medicine, Faculty of Medicine, Lambung Mangkurat University, Banjarmasin, South Kalimantan, Indonesia.

Email: haryati@ulm.ac.id

has smoked for the last six years with one cigarette/day (Brinkman index < 200). He denied having a history of trauma, cough, breathlessness, chest pain, fever, sweats, or malignancy. There was no family cancer history. The patient was a teacher. The patient's review of systems (ROS) yielded no significant findings of pulmonary symptoms. Upon auscultation, the patient's lungs were clear. Only found paraplegic.

Upon arrival at the hospital, radiographic imaging was conducted as an X-ray and computed tomography (CT) scan of the spine. The X-ray revealed the presence of lumbosacral spondylosis and paralumbar muscle spasm; meanwhile, a compressed fracture was identified at the T7 level, resulting in compression within the spinal canal in the CT scan. The magnetic resonance imaging (MRI) scan revealed corpus destruction, pedicle involvement, and spinal canal stenosis in the thoracic vertebrae 7, indicating a possible diagnosis of metastasis process (Figure 1A). The radiographic image of the pre-operative chest X-ray appeared to look normal, as depicted in Figure 1B. Subsequently, the patient underwent a laminectomy and posterior stabilization procedure of T5-6 and 8-9 (Figure 2A). The adenocarcinoma metastasis diagnosis (Figure 2B) was confirmed through biopsies of the vertebral lesions. Subsequent examination utilizing chest CT-Scan unveiled the presence of a solitary pulmonary nodule located in the anterior segment of the left lung, measuring 26 x 25 x 30 mm in diameter (Figure 2B). Carcinoma embryonic antigen (CEA) was 28.23 ng/ml. The identification of a mutation in the Epidermal Growth Factor Receptor (EGFR) gene resulting in the deletion of Exon 19 and 21 L858R was made. The administration of a second-generation tyrosine kinase inhibitor, afatinib 40 mg daily, is being employed as a targeted therapy for the patient. Zolendronic acid is also scheduled as an anti-bone destruction treatment. To this date, his VAS has been reduced to 1, and the patient has survived over 12 months.

## Discussion

This case report presents a man, 59 years old, who was referred to our hospital after experiencing worsening symptoms of back pain. Ultimately, a diagnosis of lung cancer was made when an MRI revealed evidence that was consistent with the presence of bone metastases, and a chest CT scan revealed a solitary pulmonary nodule. One of the primary explanations for the patient's back pain is the presence of vertebral metastases, which are the cause of bone pain that is associated with cancer.

A case-control study revealed that individuals who ultimately obtained a lung cancer diagnosis frequently experienced initial respiratory symptoms. On the contrary, bone pain is an infrequent symptom, manifesting in as few as 25% of patients, whereas the prevalence of systemic symptoms like weight loss is variable [9]. A casual smoker, our patient exhibited none of the typical respiratory symptoms associated with lung cancer. He was afflicted with only bone pain and systemic symptoms.

Previously published case reports have documented patients who had musculoskeletal issues that were ultimately attributed to lung cancer. A subset of patients reported spinal pain and subsequently received a diagnosis of skeletal and/or vertebral metastases [5, 9]. Imaging detected each tumor in earlier cases. When there are no abnormal laboratory or radiographic findings, healthcare professionals should contemplate utilizing modern imaging techniques such as MRI or CT-Scan to screen for malignancy as a source of pain, as conventional radiography exhibits limited sensitivity in detecting bone metastases [7, 9, 10].

Our case shows how metastatic bone disease might be missed in musculoskeletal complaints. Radiating low back pain, in this case, can be misconstrued as a degenerative spinal ailment. Although the patient had no lung cancer signs, he was an older man with unexplained weight loss and loss of appetite and did not respond to conservative

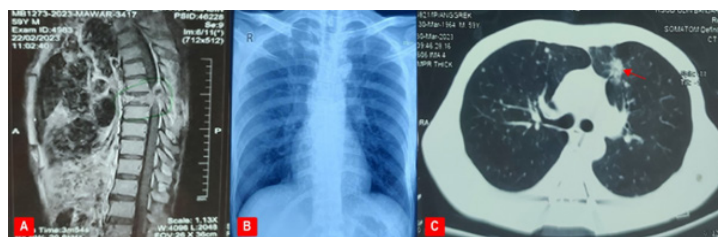


Figure 1. A. The Pre-operative MRI Revealed Corpus Destruction, Pedicle Involvement, and Spinal Canal Stenosis in the Thoracic Vertebrae 7. B. Chest X-ray pre-operative looked normal. C. A chest CT scan detected a solitary pulmonary nodule with a diameter of 26 x 25 x 30 mm in the anterior segment of the left lung.

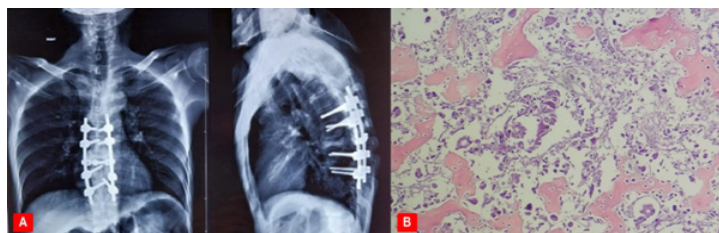


Figure 2. A. X-ray Post Laminectomy and Posterior Stabilization of T5-6, 8-9. B. Biopsies of the vertebral lesion revealed metastasis adenocarcinoma (100 x magnification).

management. These are all warning signs that indicate the presence of serious diseases like cancer. In our case, we also did some research on lung cancer. However, a conventional chest X-ray within normal range but using a chest CT scan made clear to us that lung cancer was present.

Lung cancer with spinal metastasis is managed based on its extent, location, histology, and patient health. A holistic and multimodal treatment includes surgery, radiation, systemic therapy, and pain management, which are used to improve quality of life [5, 11]. Surgery for spinal metastases aims to reduce discomfort and maintain neurological function and spinal stability. Acute metastatic spinal cord compression symptoms were present in our patient. Therefore, the procedure of posterior decompression with internal fixation effectively treated the metastatic spinal cord compression (MSCC) and provided support to his spine [12].

In Asians, EGFR-associated adenocarcinoma is more common than other NSCLC forms and typically metastasizes intra and extrathoracic. EGFR tyrosine kinase inhibitors (TKIs) extend progression-free survival (PFS) to 10 months in nearly 70% of NSCLC patients with activating EGFR gene mutations (most often L858R substitution in exon 21 or deletion in exon 19) in the first line of treatment [3, 8], as present in our patient. The retrospective analysis with lung cancer bone metastases indicated that EGFR inhibitors improved prognosis for adenocarcinoma patients, and paired with surgery and radiotherapy, they may extend survival [12]. After laminectomy and posterior stabilization, our case report is given Afatinib 40 mg daily, a second-generation tyrosine kinase inhibitor. Zoledronic acid is also scheduled as anti-bone destruction. Lack of resources prevents radiation.

In conclusion, this case highlights the need for lung cancer screening and the need to closely watch for warning signs in cases of back pain, such as the persistent aggravation of symptoms despite therapy. Curiously, the presence of back discomfort ultimately resulted in the diagnosis, even though there were no typical symptoms related to the lungs.

## Acknowledgments

### *Statement of Transparency and Principals:*

- Author declares no conflict of interest
- Study was approved by Research Ethic Committee of author affiliated Institute .
- Study's data is available upon a reasonable request.
- All authors have contributed to implementation of this research.

## References

1. Sung H, Ferlay J, Siegel RL, Laversanne M, Soerjomataram I, Jemal A, Bray F. Global Cancer Statistics 2020: GLOBOCAN Estimates of Incidence and Mortality Worldwide for 36 Cancers in 185 Countries. *CA: a cancer journal for clinicians*. 2021 05;71(3):209-249. <https://doi.org/10.3322/caac.21660>
2. Ali Mohammed Hammamy R, Farooqui K, Ghadban W. Sclerotic Bone Metastasis in Pulmonary Adenocarcinoma. *Case Reports in Medicine*. 2018;2018:1903757. <https://doi.org/10.1155/2018/1903757>
3. Krawczyk P, Nicoś M, Ramlau R, Powrózek T, Wojas-Krawczyk K, Sura S, Jarosz B, et al. The incidence of EGFR-activating mutations in bone metastases of lung adenocarcinoma. *Pathology oncology research: POR*. 2014 01;20(1):107-112. <https://doi.org/10.1007/s12253-013-9667-4>
4. Kocher F, Hilbe W, Seeber A, Pircher A, Schmid T, Greil R, Auberger J, et al. Longitudinal analysis of 2293 NSCLC patients: a comprehensive study from the TYROL registry. *Lung Cancer (Amsterdam, Netherlands)*. 2015 02;87(2):193-200. <https://doi.org/10.1016/j.lungcan.2014.12.006>
5. Inban P, Zahdeh T, Chandrasekaran SH, Intsiful TA, Gowthavaram CA, Ebong AK, Kejela Y, et al. Non-small Cell Lung Carcinoma With Metastases to Various Levels of Vertebra: A Case Report and Literature Review. *Cureus*. 15(4):e37851. <https://doi.org/10.7759/cureus.37851>
6. Mohammadi S, Abouzaripour M, Shariati N, Fathi F, Gholami Farashah MS, Hesam Shariati MB. Vertebral Fractures Due to Metastatic Tumors: A Case Report. *ACTA MEDICA IRANICA*. 2021 01 10;58. <https://doi.org/10.18502/acta.v58i11.5149>
7. Vasser M, Koroscil M. When Back Pain Turns Deadly: An Unusual Presentation of Lung Cancer. *Respiratory Medicine Case Reports*. 2020;29:101009. <https://doi.org/10.1016/j.rmcr.2020.101009>
8. Aoude AA, Amiot L. Surgical treatment of a patient with lung cancer metastasized to the spine with EGFR mutation: A case report. *International Journal of Surgery Case Reports*. 2012;3(10):510-512. <https://doi.org/10.1016/j.ijscr.2012.07.002>
9. Chu EC, Trager RJ, Lee WT, Cheong BKC, Hei SYM. Lung Cancer With Vertebral Metastases Presenting as Low Back Pain in the Chiropractic Office: A Case Report. *Cureus*. 2023 02;15(2):e34821. <https://doi.org/10.7759/cureus.34821>
10. Mabry LM, Ross MD, Tonarelli JM. Metastatic cancer mimicking mechanical low back pain: a case report. *The Journal of Manual & Manipulative Therapy*. 2014 08;22(3):162-169. <https://doi.org/10.1179/2042618613Y.0000000056>
11. D'Antonio C, Passaro A, Gori B, Del Signore E, Migliorino MR, Ricciardi S, Fulvi A, Marinis F. Bone and brain metastasis in lung cancer: recent advances in therapeutic strategies. *Therapeutic Advances in Medical Oncology*. 2014 05;6(3):101-114. <https://doi.org/10.1177/1758834014521110>
12. Xu S, Yu X, Xu M. Long-term survival of a patient with lung cancer metastasis to the spine following surgical treatment combined with radiation and epithelial growth factor receptor inhibitor therapy: A case report. *Experimental and Therapeutic Medicine*. 2015 01;9(1):117-119. <https://doi.org/10.3892/etm.2014.2055>



This work is licensed under a Creative Commons Attribution-Non Commercial 4.0 International License.