

Insights into Clinical Characteristics and Management Strategies: A Case Series of Granulosa Cell Tumors

Sumedha Gupta, Dheer Singh Kalwaniya, Archana Mishra

Department of Obstetrics and Gynaecology, Vardhman Mahavir Medical College and Safdarjung Hospital, New Delhi, India.

Abstract

Background: Granulosa cell tumors (GCTs) are rare neoplasms with predominantly low malignant potential, primarily affecting peri-menopausal individuals. This case series investigates six patients diagnosed with GCT, emphasizing clinical features, prognostic markers, and treatment strategies. **Methods:** This retrospective analysis focuses on patients diagnosed with GCT at Safdarjung Hospital between June 2022 and June 2023. Data collection included demographics, clinical presentations, diagnostic findings, treatment modalities, and follow-up outcomes. **Results:** The case series comprised various presentations, ranging from asymptomatic masses to complications such as ovarian torsion and tumor rupture. Most patients presented with hormonally active tumors, predominantly producing estrogen. Surgical management, including unilateral salpingo-oophorectomy or total abdominal hysterectomy with bilateral salpingo-oophorectomy, was the primary treatment modality. Prognostic factors such as tumor size, stage, and mitotic index were identified, guiding clinical decision-making. Close surveillance post-surgery was essential due to the potential for late recurrences. **Conclusion:** This case series enhances understanding of ovarian GCTs, providing insights into their clinical management and prognosis. Early detection, prognostic marker assessment, and vigilant surveillance are crucial for optimizing patient outcomes.

Keywords: Granulosa cell tumor- Torsion- Rupture- Sex cord-stromal tumor- Ovarian cancer

Asian Pac J Cancer Care, 10 (1), 303-308

Submission Date: 08/13/2024

Acceptance Date: 11/15/2024

Introduction

Granulosa Cell Tumor of the Ovary (GCT) represents a rare subset of ovarian cancers, comprising approximately 5% of malignant ovarian tumors [1, 2]. This type of cancer can be categorized into two distinct subsets based on histological and clinical features: adult-type GCT (AGCT) and juvenile GCT (JGCT) [3]. AGCT is predominant, accounting for approximately 95% of all GCT cases [4]. AGCT typically presents with notable clinical endocrine manifestations, often leading to diagnosis at an early stage in 78%-91% of cases [5]. Prolonged exposure to endogenous estrogen is implicated in AGCT pathogenesis, potentially leading to conditions like endometrial hyperplasia or carcinoma [6]. AGCT commonly affects women in their perimenopausal or early postmenopausal stages, with peak diagnosis occurring between 50 and 54 years of age [2]. Surgery stands as the primary treatment modality for ovarian AGCT. Advanced or recurrent cases may necessitate adjuvant therapies such as radiotherapy,

chemotherapy, hormone therapy, or targeted therapy. Studies have revealed a high prevalence (approximately 97%) of somatic missense mutations in the FOXL2 transcription factor among AGCT cases [7]. Importantly, this mutation is distinct to AGCT and absent in other cancers, including JGCTs. The presence of the FOXL2 mutation serves as a crucial diagnostic and therapeutic marker, offering insights into AGCT pathogenesis and potential treatment avenues. Despite significant research efforts, the precise pathogenesis of AGCT remains elusive, necessitating further exploration and investigation.

Here we describe case series includes all the cases of ovarian GCT diagnosed at Safdarjung Hospital between June 2022 to June 2023. This case series highlights the diverse natural progression and initial presentations of adult-type Granulosa Cell Tumors (GCTs), underlining the necessity for continuous, indefinite long-term follow-up protocols.

Corresponding Author:

Dr. Sumedha Gupta

Department of Obstetrics and Gynaecology, Vardhman Mahavir Medical College and Safdarjung Hospital, New Delhi, India.

Email: Sumedhagupta91@gmail.com

Case Series

Case 1

A 40-year-old female presented to the gynaecology emergency department with symptoms of acute abdomen and hypovolemic shock. On examination, she exhibited a rapid and thready pulse of 120 beats per minute accompanied by a blood pressure of 90/60 mmHg. Immediate resuscitation was initiated with intravenous fluids. Ultrasonography revealed gross hemoperitoneum associated with an ovarian mass, prompting a decision for exploratory laparotomy. During surgery, a large mass measuring 10x9x5 cm originating from the left ovary was discovered, with evidence of capsular rupture and significant hemoperitoneum amounting to 2 litres (Figure 1). Intraoperative blood transfusion was administered to stabilize the patient. The patient underwent left salpingo-oophorectomy. Postoperatively, the patient tolerated the procedure well. Subsequent histopathological analysis confirmed the presence of an Adult Granulosa Cell Tumor (Figure 2), with immunohistochemistry showing positivity for calretinin, vimentin, and CD 56. The final staging was determined to be stage 1C.

Following surgery, contrast-enhanced computed tomography of the chest, abdomen, and pelvis demonstrated no residual disease. Subsequently, the patient underwent completion surgery, including total abdominal hysterectomy with right salpingo-oophorectomy and infracolic omentectomy. Additionally, a planned course of postoperative chemotherapy was initiated, comprising 6 cycles of paclitaxel and carboplatin. As of the latest follow-up, spanning 6 months, the patient remains in remission, indicative of a favorable response to treatment.

Case 2

A 50-year-old post-menopausal woman presented with symptoms of abdominal distention and lower abdominal pain for 3 months. Upon examination, a pelvic mass measuring approximately 10 x 12 cm, firm in consistency, solid cystic with restricted mobility, was palpated, extending up to the umbilicus. Ultrasonography revealed a large cystic mass with a solid component measuring 13x12x9.3 cm in the left adnexa, with the uterus appearing normal in size but with a thickened endometrium. Other findings on ultrasonography were within normal limits, and tumor marker levels were within normal ranges.

Subsequent contrast-enhanced computerized tomography (CECT) confirmed the presence of a solid-cystic mass without any evidence of extra-pelvic spread. Laparotomy revealed a left ovarian mass measuring 10x15x10 cm along with a bulky uterus. Total abdominal hysterectomy, left salpingo-oophorectomy, and infracolic omentectomy were performed. Histopathological analysis confirmed the presence of an adult Granulosa Cell Tumor (GCT), which was further corroborated by immunohistochemistry. The final staging of the tumor was determined to be stage 1A. Following the surgical intervention, the patient was placed under surveillance and commenced routine follow-up visits. Presently, the patient is on routine follow-up and in remission.

Case 3

A 66-year-old female presented with a two-month history of abdominal pain and decreased appetite. Notably, she had undergone a hysterectomy 19 years prior due to abnormal uterine bleeding. Physical examination revealed a pelvic mass extending up to the xiphoid process, further confirmed by MRI to be a multiseptated cyst with solid and cystic components measuring approximately 27 x 24 x 16 cm. Additionally, right hydronephrosis was noted. Tumor marker levels were within normal limits.

Given the findings, the patient underwent laparotomy, revealing an irregular complex solid cystic mass measuring 29 x 30 x 25 cm originating from the right ovary, while the left ovary and uterus appeared normal. Pelvic and para-aortic lymph nodes were not enlarged. Total abdominal hysterectomy and bilateral salpingo-oophorectomy, along with infracolic omentectomy and peritoneal biopsy, were performed. Subsequent histopathological analysis confirmed the presence of an adult Granulosa Cell Tumor (GCT), leading to the staging of stage 1A GCT. Following the surgical intervention, the patient was placed under surveillance. She has since been regularly following up and remains in remission.

Case 4

A 30-year-old woman undergoing treatment for primary infertility presented with a five-month history of abdominal distention and abdominal pain. Ultrasonography revealed a right adnexal cystic lesion measuring 14x10x15 cm. Tumor marker levels were within normal limits. Subsequent contrast-enhanced Magnetic Resonance Imaging (CEMRI) indicated a complex solid cystic mass measuring 14x15x12 cm originating from the right adnexa, with the left ovary and uterus appearing normal and maintaining fat planes with adjoining structures (Figure 3). Endometrial aspirate findings suggested proliferative endometrium.

The patient underwent planned laparotomy, revealing a solid mass originating from the right ovary with capsular rupture, measuring approximately 17x15x18 cm. Additionally, tumor deposits were observed on the omentum, and peritoneum (including over the sigmoid and bladder peritoneum), with the largest deposit measuring 3x2 cm. Pelvic and para-aortic lymph nodes were not enlarged. Right salpingo-oophorectomy, infracolic omentectomy, and removal of multiple peritoneal deposits

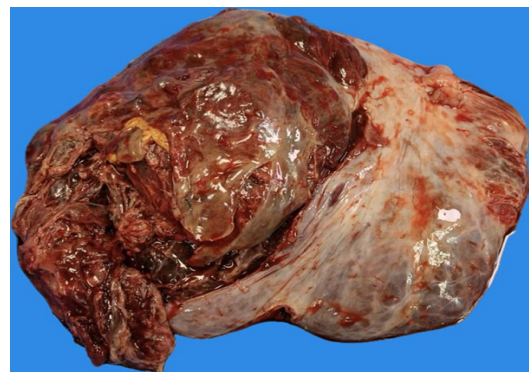

Figure 1. Large Tan Yellow Solid Mass with Capsular Rupture

Table 1. Summarized Case Details for the Presented Series

S.NO	AGE	Presenting Complaint	Imaging	Surgical Management	Intraop Findings	Histopathology Report	Management
1	40yr	Acute abdomen with Hypovolemic shock	USG- Gross hemoperitoneum with ovarian mass	Exploratory laparotomy followed by left Salpingo-oophorectomy	Large mass 10x9x5 cm arising from left ovary with capsular rupture 2 litres of hemoperitoneum	Adult Granulosa cell tumor IHC-Positive for calretinin, vimentin, CD 56.	Final stage – Granulosa cell tumor stage 1C CECT – No evidence of residual disease Completion surgery followed by Chemotherapy
2	53yr	Postmenopausal bleeding with abdominal distention	USG- Large cystic mass with solid component measuring 13x12x9.3 cm in right adnexa with uterus normal size with thickened endometrium CECT – Large left adnexal solid cystic mass	Staging laparotomy followed by Total abdominal hysterectomy and bilateral Salpingo-oophorectomy with infracolic omentectomy and peritoneal biopsy	Left ovarian mass 10x15x10 cm with bulky uterus Pelvic and para-aortic lymph nodes not enlarged.	Adult Granulosa cell tumor IHC-Positive for vimentin and CD 99.	Final stage – Granulosa cell tumor stage 1A Surveillance
3	66yr	Pain abdomen and weight loss	USG- Large well defined heterogeneous multiseptated mass with coarse internal echoes measuring 27x24x16 cm. B/I ovaries not seen separately. CEMRI – Right ovarian complex solid cystic mass with internal septations measuring 28x29x19 cm. left ovary and uterus normal	Staging laparotomy followed by Total abdominal hysterectomy and bilateral Salpingo-oophorectomy with infracolic omentectomy and peritoneal biopsy	Right ovarian complex solid cystic mass 29x30x25 cm, left ovary and uterus normal. Pelvic and para-aortic lymph nodes not enlarged.	Adult Granulosa cell tumor IHC-Positive for vimentin, Inhibin and calretinin	Final stage – Granulosa cell tumor stage 1A Surveillance
4	30 yr	Abdominal distention and pain lower abdomen	USG- right adnexal cystic lesion 14x10x15 cm, left adnexa clear, uterus normal CEMRI- Right adnexal complex solid cystic mass 14x15x12 cm, left ovary and uterus normal with maintained fat planes with adjoining structures.	Staging laparotomy followed by Right salpingo-oophorectomy with infracolic omentectomy with removal of multiple peritoneal deposits.	Right ovarian solid mass with capsular rupture approx. 17x15x18 cm, omentum studded with tumor deposit, peritoneal deposits present over sigmoid and bladder peritoneum largest being 3x2 cm. Pelvic and para-aortic lymph nodes not enlarged	Adult Granulosa cell tumor IHC-Positive for vimentin, Inhibin and calretinin	Final stage – Granulosa cell tumor stage 3C. Oocyte cryopreservation followed by Chemotherapy. Received 4 cycle of Paclitaxel and Carboplatin. Planned for completion surgery after child bearing.
5	60yr	Abdominal distention and abdominal pain	PET-CT- A large solid cystic mass 25x28x18 cm, b/I adnexa not seen separately, omental deposits present, gross ascites and moderate right pleural effusion.	Tricent biopsy from ovarian mass, cell block cytology from pleural effusion	N/A	Adult Granulosa cell tumor IHC-Positive for WTI, Inhibin and calretinin	Final stage – Granulosa cell tumor stage 4A. Planned for Neoadjuvant Chemotherapy
6	39yr	Severe abdominal pain	CEMRI- Right ovarian solid cystic mass 11x10x7 cm, left ovary and uterus normal. Rest of the organs normal	Exploratory laparotomy followed by Right salpingo-oophorectomy	Right complex solid cystic mass 11x10x7cm with torsion.	Incidentally diagnosed Adult Granulosa cell tumor IHC-Positive for vimentin, Inhibin and calretinin	PET CT –No residual disease. Completion surgery followed by chemotherapy

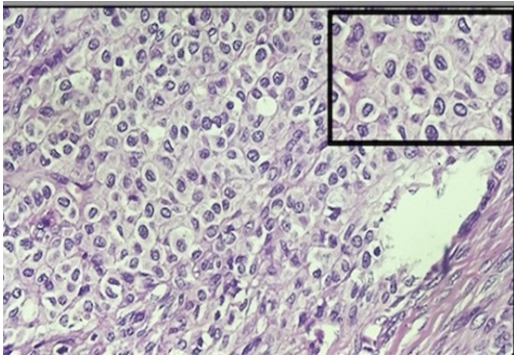


Figure 2. 40x H and E Shows Individual Tumor Cell with Angulated Nucleus and Longitudinal Nuclear Groove Giving Coffee Bean Appearance Suggestive of Adult Granulosa Cell Tumor.

were performed. Histopathological analysis confirmed the presence of an Adult Granulosa Cell Tumor, with immunohistochemistry showing positivity for vimentin, Inhibin, and calretinin. The final staging of the tumor was determined to be stage 3C.

Following discussion in a multidisciplinary team meeting, the patient underwent oocyte cryopreservation followed by four cycles of Paclitaxel and Carboplatin chemotherapy. Completion surgery was planned post-childbearing. The patient has been regularly followed up and remains in remission.

Case 5

A 60-year-old woman presented to the gynaecology clinic with complaints of abdominal pain, abdominal distention, and dyspnea. Physical examination revealed tachycardia with a pulse rate of 102 beats per minute and a blood pressure of 128/90 mmHg. Abdominal examination demonstrated an overdistended abdomen with the presence of ascites.

Further investigations including chest X-ray and abdominal ultrasound revealed moderate pleural effusion and gross ascites, along with a large solid-cystic mass originating from the pelvis. Both ovaries were unable to be discerned separately from the mass. Following stabilization, the patient underwent ascitic and pleural tapping. Subsequently, a positron emission tomography (PET) scan was performed, confirming the presence of a large solid cystic mass measuring 25x28x18 cm, with the bilateral adnexa not distinct from the mass. Omental deposits, gross ascites, and moderate right pleural effusion were also noted.

A true cut biopsy was conducted, and samples from pleural and ascitic taps were sent for cell block cytology. The final histopathology report from the biopsy revealed an Adult Granulosa Cell Tumor, with immunohistochemistry indicating positivity for WT1, Inhibin, and Calretinin. Malignant cells were also identified in the pleural fluid cell block. The tumour was staged as stage 4A. The case was discussed in the multidisciplinary team meeting and the patient was scheduled to undergo four cycles of paclitaxel and carboplatin as neoadjuvant chemotherapy. Subsequently, the patient will be planned for Interval debulking surgery as per the response to the

chemotherapeutic agent.

Case 6

A 39-year-old woman presented to the emergency room with severe abdominal pain, accompanied by a three-month history of intermittent abdominal discomfort. On examination, a pelvic mass equivalent to a 24-week size uterus was palpated, demonstrating solid cystic consistency with restricted mobility. A recent contrast-enhanced magnetic resonance imaging (CEMRI) scan performed a week prior indicated the presence of a solid cystic mass measuring 11x10x7 cm originating from the right ovary, with the left ovary and uterus appearing normal. Notably, all tumor markers were within normal ranges. Given the urgent clinical presentation, the patient underwent immediate laparotomy, revealing a large mass originating from the right adnexa measuring approximately 11x10x7 cm with evidence of torsion. Subsequently, right salpingo-oophorectomy was performed, and the patient recovered well postoperatively. However, incidentally, the histopathology report revealed an Adult Granulosa Cell Tumor, with immunohistochemistry indicating positivity for vimentin, Inhibin, and calretinin.

Following surgery, a positron emission tomography (PET) scan was conducted, which indicated no evidence of residual disease. As the patient had completed her family planning, she underwent completion surgery consisting of a total abdominal hysterectomy, left salpingo-oophorectomy, and infracolic omentectomy. The patient was then placed under surveillance, with the final staging of stage 1A adult GCT was made after staging.

Description of all the cases presented in Table 1.

Discussion

Ovarian granulosa cell tumors (GCTs) are infrequent neoplasms known for their indolent course and a favourable prognosis. Recent studies have highlighted a link between these tumors and mutations in the Forkhead box L2 gene. This gene plays a critical role in ovarian development,

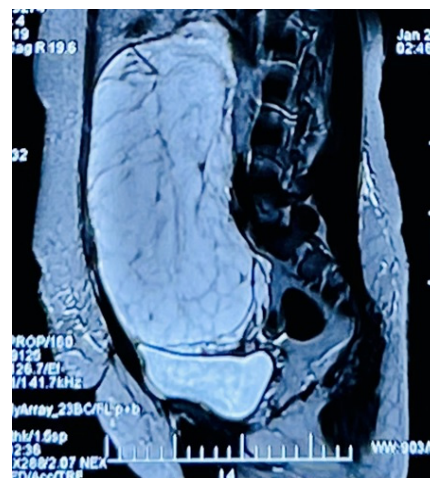

Figure 3. T2 Weighted CEMRI with Complex Solid Cystic Mass Measuring 14x15x12 cm Originating from the Right Adnexa.

particularly during gonadogenesis [8]. Importantly, ovarian juvenile GCTs often co-occur with multiple enchondromatosis conditions like Maffucci syndrome and Ollier disease. Thus, when encountering an adnexal mass in young females with these conditions, considering the possibility of ovarian juvenile GCTs is essential.

Granulosa cell tumors (GCTs) predominantly affect individuals in the peri-menopausal age group, peaking between 50 and 55 years old, with bilateral involvement seen in only 2% of cases [8]. These tumors are hormonally active, mainly producing estrogen. They are categorized into adult and juvenile types based on clinicopathological features, with the adult variant comprising 95% of cases. Symptoms vary widely, from asymptomatic masses to signs of hyperestrogenism such as precocious puberty, abnormal uterine bleeding, and postmenopausal bleeding [9]. In rare instances, GCTs may secrete androgens, leading to manifestations like clitoromegaly or hirsutism, although no such cases were seen in our case series. While ovarian torsion due to GCTs is uncommon, occasional reports exist, especially in the juvenile type. Tumor rupture occurs in about 10% of cases, presenting with symptoms like abdominal pain and hemoperitoneum [10]. Our case series encountered various presentations, including asymptomatic masses, mild discomfort, ascites, ruptured ovarian masses, and ovarian torsion. Although some patients may experience secondary amenorrhea due to inhibin B-mediated suppression of follicle-stimulating hormone response [11], this was not observed in our case series. Inhibin B, a crucial ovarian glycoprotein, plays a role in the normal menstrual cycle by preventing further follicle recruitment. Positive immunohistochemical staining for inhibin is diagnostically significant in GCTs. Adult-type GCTs exhibit diverse histological morphologies, typically characterized by oval cells with nuclear grooves (coffee bean cells) and Call-Exner body formation. Although mitotic activity is usually low, a higher rate (≥ 4 MF/10 HPF) is associated with poorer prognosis and increased recurrence risk [10].

Juvenile-type GCTs share gross morphological features with adult tumors but often have a higher mitotic rate and lack the characteristic nuclear grooves. However, we did not encounter any juvenile-type GCTs in our series.

Granulosa cell tumors (GCTs) are characterized by their low malignant potential, often being detected early, with around 80% diagnosed at stage I disease. This early detection contributes to a high five-year survival rate exceeding 90%, partly attributed to clinical manifestations linked to inhibin and estrogen expression [12]. In our series, the majority of patients were diagnosed at an early stage, with only two cases showing advanced-stage disease. Identifying prognostic factors for GCTs is challenging due to their rarity and the extended follow-up period required. Serum markers like Inhibin B, sometimes combined with anti-Müllerian hormone, have shown promise in anticipating clinical recurrence well in advance [12]. Clinical and pathological risk factors for recurrence in early-stage GCTs have been assessed through retrospective analyses. Thomakos and colleagues [13] identified tumor size, stage, and mitotic

index as independent predictors for recurrence. In our case series, advanced-stage disease and tumor rupture were observed, highlighting the need for close monitoring. The Multicenter Italian Trials in Ovarian cancer (MITO-9) study by Mangili et al. examined recurrent GCT cases and found no significant difference in overall survival between patients who received chemotherapy after secondary surgery and those who did not [14].

Surgical management typically involves unilateral salpingo-oophorectomy or total abdominal hysterectomy with bilateral salpingo-oophorectomy, with staging procedures recommended. There is no consensus regarding the necessity of lymphadenectomy. Adjuvant therapy's efficacy for high-risk patients remains unexplored in randomized controlled trials. Prolonged surveillance involving periodic clinical, biochemical, and radiologic assessments is crucial due to the potential for late recurrence following initial surgical management [15].

In conclusion, granulosa cell tumors (GCTs) present with varied clinical manifestations, ranging from asymptomatic masses to hormonal imbalances and rare complications like torsion or rupture. While most cases are diagnosed at an early stage with favourable outcomes, advanced-stage disease and recurrence pose challenges. Prognostic factors such as tumor size, stage, and mitotic index guide management decisions, with surgical resection as the primary treatment modality. Adjuvant therapies' efficacy remains uncertain, necessitating prolonged surveillance for potential late recurrences. Close monitoring and further research are warranted to optimize management strategies and improve long-term outcomes for patients with GCTs.

Acknowledgements

Nil

Conflict of Interest

Nil

Funding

Nil

References

1. Pectasides D, Pectasides E, Psyrris A. Granulosa cell tumor of the ovary. *Cancer Treatment Reviews*. 2008 02;34(1):1-12. <https://doi.org/10.1016/j.ctrv.2007.08.007>
2. Unkila-Kallio L, Tiitinen A, Wahlström T, Lehtovirta P, Leminen A. Reproductive features in women developing ovarian granulosa cell tumour at a fertile age. *Human Reproduction (Oxford, England)*. 2000 03;15(3):589-593. <https://doi.org/10.1093/humrep/15.3.589>
3. Jamieson S, Fuller PJ. Molecular pathogenesis of granulosa cell tumors of the ovary. *Endocrine Reviews*. 2012 02;33(1):109-144. <https://doi.org/10.1210/er.2011-0014>
4. Young RH, Dickersin GR, Scully RE. Juvenile granulosa cell tumor of the ovary. A clinicopathological analysis of 125 cases. *The American Journal of Surgical Pathology*. 1984 08;8(8):575-596. <https://doi.org/10.1097/00000478-198408000-00002>

5. Savage P, Constenla D, Fisher C, Shepherd JH, Barton DP, Blake P, Gore ME. Granulosa cell tumours of the ovary: demographics, survival and the management of advanced disease. *Clinical Oncology (Royal College of Radiologists (Great Britain))*. 1998;10(4):242-245. [https://doi.org/10.1016/s0936-6555\(98\)80008-3](https://doi.org/10.1016/s0936-6555(98)80008-3)
6. Case records of the Massachusetts General Hospital. Weekly clinicopathological exercises. Case 10-1995. A 56-year-old woman with abdominal pain, anemia, and a pelvic mass. *The New England Journal of Medicine*. 1995 03 30;332(13):876-881. <https://doi.org/10.1056/NEJM199503303321308>
7. Jamieson S, Butzow R, Andersson N, Alexiadis M, Unkila-Kallio L, Heikinheimo M, Fuller PJ, Anttonen M. The FOXL2 C134W mutation is characteristic of adult granulosa cell tumors of the ovary. *Modern Pathology: An Official Journal of the United States and Canadian Academy of Pathology, Inc.* 2010 Nov;23(11):1477-1485. <https://doi.org/10.1038/modpathol.2010.145>
8. Shah SP, Köbel M, Senz J, Morin RD, Clarke BA, Wiegand KC, Leung G, et al. Mutation of FOXL2 in granulosa-cell tumors of the ovary. *The New England Journal of Medicine*. 2009 06 25;360(26):2719-2729. <https://doi.org/10.1056/NEJMoa0902542>
9. Niwa K, Yano R, Mori S, Yamaguchi Y, Narikawa N, et al. Androgenic adult granulosa cell tumor with secondary amenorrhea and elevated luteinizing hormone. *ResearchGate*. 2024 Oct 22;. <https://doi.org/10.7243/2052-7896-1-9>
10. Hastings RS, Powers RD. Abdominal pain in the ED: a 35 year retrospective. *The American Journal of Emergency Medicine*. 2011 09;29(7):711-716. <https://doi.org/10.1016/j.ajem.2010.01.045>
11. Agha-Hosseini M, Aleyaseen A, Safdarian L, Kashani L. Secondary amenorrhea with low serum luteinizing hormone and follicle-stimulating hormone caused by an inhibin A- and inhibin B-producing granulosa cell tumor. *Taiwanese Journal of Obstetrics & Gynecology*. 2009 03;48(1):72-75. [https://doi.org/10.1016/S1028-4559\(09\)60040-1](https://doi.org/10.1016/S1028-4559(09)60040-1)
12. Sehouli J, Drescher FS, Mustea A, Elling D, Friedmann W, Kühn W, et al. Granulosa cell tumor of the ovary: 10 years follow-up data of 65 patients. *Anticancer Research*. 2004;24(2C):1223-1229.
13. Thomakos N, Biliatis I, Koutroumpa I, Sotiropoulou M, Bamias A, Lontos M, Vlachos G, Rodolakis A. Prognostic factors for recurrence in early stage adult granulosa cell tumor of the ovary. *Archives of Gynecology and Obstetrics*. 2016 Nov;294(5):1031-1036. <https://doi.org/10.1007/s00404-016-4135-5>
14. Mangili G, Sigismondi C, Frigerio L, Candiani M, Savarese A, Giorda G, Lauria R, et al. Recurrent granulosa cell tumors (GCTs) of the ovary: a MITO-9 retrospective study. *Gynecologic Oncology*. 2013 07;130(1):38-42. <https://doi.org/10.1016/j.ygyno.2013.04.047>
15. Fotopoulou C, Savvatis K, Braicu E, Brink-Spalink V, Darb-Esfahani S, Lichtenegger W, Sehouli J. Adult granulosa cell tumors of the ovary: tumor dissemination pattern at primary and recurrent situation, surgical outcome. *Gynecologic Oncology*. 2010 Nov;119(2):285-290. <https://doi.org/10.1016/j.ygyno.2010.06.031>



This work is licensed under a Creative Commons Attribution-Non Commercial 4.0 International License.