

# Fast-track Palliation: Evaluating Accelerated Hypofractionated Radiotherapy in Advanced Oral Cavity Cancer

Kaluvoya Ramanaiah, Moushmi Varadarajan, Gautam Vydia Vedagiri, Sadanand Sharosh Gandhi, Mukesh Balasundaram, Alexander John

Department of Radiation Oncology, Cancer Institute (WIA), Adyar, Chennai, Tamilnadu, India.

## Abstract

**Background:** Advanced oral cavity squamous cell carcinoma (OCSCC) in patients with poor performance status presents significant challenges in management, as many are ineligible for curative treatment. Palliative care, particularly radiation therapy, aims to alleviate symptoms and improve quality of life. Accelerated hypofractionated radiotherapy offers a shorter, more intensive treatment course, which may improve patient compliance and provide rapid symptom control. The aim of this study was to evaluate the feasibility, symptom control, toxicity profile, and overall survival of a 5-day course of accelerated hypofractionated palliative radiation therapy in patients with locally advanced OCSCC who are not candidates for curative treatment. **Methods:** This prospective single-arm pilot study included 8 patients with advanced OCSCC (ECOG performance status 2-3), who were treated with a total dose of 30Gy in 10 fractions of 300cGy twice daily over 5 days. Patients were assessed for symptom control, toxicity, and overall survival (OS) at 1 year. Symptom control was evaluated immediately post-treatment and mucosal/dermal toxicities were monitored at 4 weeks. **Results:** The median age of patients was 71 years (range 62-80). All patients completed the treatment. Primary symptom control was achieved in 100% of patients, with a reduced need for analgesics post-treatment. Grade 3 mucositis occurred in 5 patients, while 2 experienced Grade 2 mucositis. No Grade 4 toxicities were observed. One patient expired before the 1-month follow-up; 50% of the remaining patients achieved complete remission, and 50% had a partial response. The 1-year overall survival rate was 50%, with a median survival of 16 months (range 1-22 months). **Conclusion:** Accelerated hypofractionated palliative radiotherapy is a feasible and well-tolerated option for patients with locally advanced OCSCC who are not eligible for the conventional hypofractionated regimens. The regimen demonstrated effective symptom control with acceptable toxicity and showed comparable survival outcomes to other palliative radiation regimens. Further studies with larger cohorts are warranted to validate these findings.

**Keywords:** Advanced Oral Cavity Squamous Cell Carcinoma (OCSCC)- 5-Day Radiotherapy Regimen

*Asian Pac J Cancer Care*, 10 (1), 7-10

Submission Date: 10/21/2024

Acceptance Date: 12/08/2024

## Introduction

Head and neck cancers, including oral cavity squamous cell carcinoma, represent a significant global health burden, accounting for approximately 900,000 new cases and 400,000 deaths annually[1]. A large subset of patients present with advanced, unresectable disease at diagnosis, often accompanied by poor performance status making them ineligible for curative treatment options. These patients typically suffer from debilitating symptoms such as pain, dysphagia, and tumor-related complications that

significantly impair their quality of life. For such cases, palliative treatments aim to alleviate symptoms and improve the quality of life rather than extend survival.

Palliative radiation therapy (RT) plays a critical role in the management of patients with advanced head and neck cancers, particularly for those not suitable for surgery or systemic therapy. Conventional radiation regimens for palliative care often involve extended treatment durations, which can pose challenges for patients with poor general

## Corresponding Author:

Ramanaiah Kaluvoya, MD

Department of Radiation Oncology, Cancer Institute (WIA), Adyar, India.

Email: ramanakaluvoya@yahoo.co.in

conditions, logistical barriers, and limited life expectancy. To address these concerns, hypofractionated radiation therapy has emerged as an attractive alternative. This approach delivers higher doses per fraction over a shorter overall treatment period, providing rapid symptom relief while minimizing the burden of prolonged hospital visits and potential radiation-related toxicity.

Accelerated hypofractionated palliative radiation regimens are particularly relevant in resource-constrained settings and for patients with poor nutritional status or compromised performance status. These regimens not only reduce the overall treatment time but also offer the possibility of improved compliance and symptom management. However, there is limited data on the feasibility and effectiveness of accelerated hypofractionated RT for oral cavity cancers in patients who are ineligible for curative intent treatment.

This prospective pilot study aims to evaluate the feasibility, symptom control, and toxicity profile of an accelerated 5-day hypofractionated radiation regimen in locally advanced oral cavity squamous cell carcinoma patients not eligible for curative treatment. Additionally, we assess the overall survival at one year, providing further insights into the potential of this regimen to offer effective palliation while maintaining acceptable toxicity levels in a vulnerable patient population.

## Materials and Methods

This is a single-arm prospective pilot study enrolling 8 eligible locally advanced oral cavity cancer patients, who were not eligible for curative treatment, and having squamous cell carcinoma histology with no history of previous irradiation. Patients with performance status based on the Eastern Cooperative Oncology Group (ECOG) 2-3 and normal blood and biochemical parameters were included (Table 1 shows baseline details, Table 2 shows TNM staging details). Previously irradiated recurrent cases and synchronous primaries, ECOG performance status 4 were excluded from the study. The primary objective of the study is to assess the primary symptom control and acute toxicity profile. The secondary objective of the study is to assess overall survival (OS) at 1 year.

All patients were treated with a total dose of 30Gy prescribed in a schedule of 300cGy per fraction, administered two times a day 8 hours apart for 5 days. The planning target volume was the Gross Tumor Volume (Primary tumor and involved nodes) with an additional margin of 2cm all around. All cases were treated using a Telecobalt machine with two opposing lateral fields. Primary symptom control was assessed immediately after the completion of therapy, and response to the treatment was assessed 4 weeks from the completion of palliative radiation therapy. Mucosal and dermal toxicities were also measured, and patients were followed up for a year. *Radiotherapy Treatment Planning and Treatment Details*

Eligible locally advanced oral cavity squamous cell cancer patients not planned for curative treatment, and attending the radiation oncology department, were

recruited in this study after ethical approval and obtaining informed consent. Before starting radiation, all patients were assessed for pain and swallowing difficulties and were started on palliative and supportive measures. All patients required opioid analgesics for pain relief, and 5/8 cases with both dysphagia and pain required NG tube insertion. The radiotherapy was delivered at Cobalt-60 Teletherapy unit. The target included primary tumors and involved nodes. Patients were treated with two opposing lateral fields, with a total dose of 30Gy prescribed in a schedule of 300cGy per fraction twice a day, 8 hours apart for a period of 5 days. Patients were assessed after 2 weeks and followed until death.

## Results

The median age of the entire cohort was 71 years (range 62-80 years). All patients completed the planned treatment. At 2 weeks, all 8 patients were reviewed, and all patients had satisfactory control of the primary symptom, with a significant reduction in dosage and frequency of analgesic support. Five of the eight patients developed Grade 3 mucositis, two patients experienced Grade 2 mucositis, and no Grade 3 or 4 skin reactions were noted. One month post-treatment, 7 patients were reviewed (1 patient had expired), with 50% of patients having a complete remission, and 30% of patients having a partial response. No progression of disease was observed at one month. At 6 months, 6 patients were on follow-up. Two out of six had progressive disease and were advised palliative systemic therapy. They were continued with symptomatic and supportive measures. Statistical analysis was carried out using STATA/SE 18.0 software. The median follow-up

Table 1. Baseline Characteristics of Patients with Advanced Oral Cavity Squamous Cell Carcinoma

Site	Number of cases
Buccal mucosa	3
Anterior tongue	2
Floor of mouth	1
Gingiva	2
Performance status	
ECOG 2	4
ECOG 3	4
Primary Concerned Symptom	
Pain and dysphagia	5
Pain	3
Histology	
Squamous cell Carcinoma Grade I	2
Squamous cell Carcinoma Grade II	6
Comorbidities	
Diabetes mellitus	2
Hypertension	2
Habits	
Tobacco chewing	6
Smoking	1

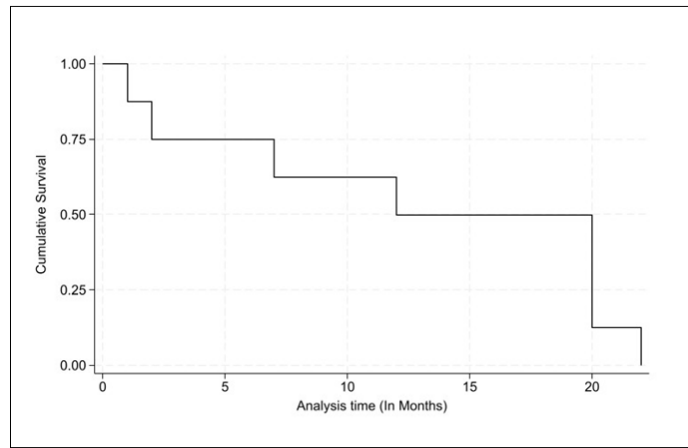


Figure 1. The Survival Curve for the Eight Patient Treated by Accelerated Hypofractionated Radiotherapy

duration for the entire cohort was 16 months (range 1-22 months), and the 1-year overall survival rate was 50%. (Overall survival is graphically represented using a Kaplan-Meier survival curve in Figure 1).

**Discussion**

For patients with advanced, unresectable head and neck cancers in poor general condition, palliative external beam radiotherapy (EBRT) is considered for symptom control. Many of these patients, suffering from poor general conditions, poor nutritional status, and economic and psychosocial burdens, are less compliant with treatment. By reducing treatment duration, hypofractionated radiation regimens play a major role in management. Hypofractionated radiation therapy offers the radiobiological advantage of reducing overall treatment time and thus mitigating the effect of accelerated repopulation in locally advanced head and neck cancers. Considerations for an optimal palliative radiotherapy schedule include significant tumor regression and symptom control within a short treatment time with acceptable side effects. While large fraction sizes in a short overall treatment duration increase tumor cell kill, there is also an increased potential for late side effects. However, late radiation toxicity is often less relevant in a palliative setting. In any anticancer therapy, disease control, overall survival (OS), and event-free survival (EFS) are the endpoints. In this study, the primary gain of palliative radiation therapy was symptom control, as meaningfully reflected by patients’ subjective responses.

Palliation and improving quality of life are of greater importance than response rates in palliative patients with limited life expectancy.

This study includes advanced oral cavity malignancy cases with impending orocutaneous fistula, extensive infratemporal fossa involvement, and large N3b nodes. Patients with poor performance status (ECOG 2-3) and limited life expectancy aimed toward palliation. A shorter radiation schedule has better patient compliance than the usual palliative radiation therapy regimen due to the early completion of treatment. Altered fractionation aims to improve the therapeutic ratio between tumor cell kill and normal tissue damage by exploiting the dissociation between acute and late effects of radiation therapy, and it also enhances cell kill by reducing the time for cell repair [2].

Our study results showed improved quality of life and effective palliation in patients with a short treatment time, without any Grade 4 toxicities (mucosal or dermal). This regimen can be considered for metastatic cases as well as for symptomatic control. Quality of life acts as an important parameter in palliative radiotherapy [3].

When comparing our data to existing literature, our study population had poorer performance status and consisted predominantly of older, nutritionally challenged patients (median age of 71 years) compared to the study by K.N. Kancherla et al., where patients were treated with palliative split-course hypofractionated radiotherapy (initial 20Gy in five fractions over 1 week, a 2-week gap, and then a further 20Gy in five fractions over 1 week). [4] Symptomatic improvement was reported in 79% of

Table 2- Primary Tumor TNM staging- (AJCC 8<sup>th</sup> Edition), for Aptients with Advanced Oral Cavity Squamous Cell Carcinoma

Site	TNM-stage	Number of cases
Buccal mucosa	T4b N1 M0	2
	T4a N0 M0	1
Anterior tongue	T4a N3b	1
	T4b N0	1
Floor of mouth	T4a N3b	1
Gingiva	T4a N3b	1
	T3 N3b	1

patients, with 39% having a complete tumor response and 33% having a partial response. Our study showed that 100% of patients had symptomatic relief, with 50% achieving complete response and 50% achieving partial response.

Compared to the QUAD-SHOT regimen where advanced head and neck cases were treated with 3.7Gy twice a day for two consecutive days and repeated every three to four weeks for a total dose of 4440cGy in three cycles along with radiosensitizing chemotherapy, the tumor response was 85.7%, with 100% of patients experiencing palliation of presenting symptoms. Minimal treatment-related morbidity was reported, and the median overall survival was seven months (range 3.7-10.4 months) [5]. Our study also showed good palliation of symptoms, acceptable mucosal and dermal toxicities, and a better median survival of 16 months (range 1-22 months).

The HYPO trial, which studied hypofractionated radiotherapy for the palliation of advanced head and neck cancer in patients unsuitable for curative treatment, showed that 67% of patients (out of 35 cases) had symptom control. Although our study had fewer patients, all cases experienced good palliation [6].

Compared to the Christie scheme studied by Abhram Al-Mamgani et al., where 158 patients with HNSCC unsuitable for curative treatment were treated with a hypofractionated scheme of 16 fractions of 3.125Gy, resulting in a median survival time of 17 months and an overall survival rate of 40% at 1 year, our study showed a comparable median overall survival of 16 months (range 1-22 months) with a 50% overall survival rate at 1 year [7].

Our study was helpful in reducing treatment time, hospital stay, economic burden, and machine load. Accelerated hypofractionated palliative radiotherapy can be considered for advanced oral cavity malignancies in suitable cases (those with advanced lesions, poor performance status, and ineligibility for curative treatment) as a feasible, well-tolerated option that provides good palliation. To the best of our knowledge, this is the first study to evaluate an accelerated hypofractionated regimen in a palliative setting. Limitations of this study include a small sample size, but it was only a pilot study. Further prospective studies with larger populations are required to ascertain our findings.

In conclusion, palliative therapy and improving the quality of life are of greater importance compared to response rates in palliative settings, especially for patients with limited life expectancy. In our study, accelerated hypofractionated radiation showed comparable outcomes with existing palliative hypofractionated radiation regimens, with less overall treatment time (5 days) and acceptable mucosal and dermal toxicities. This regimen also had better patient compliance due to the early completion of treatment.

## Acknowledgments

### Statement of Transparency and Principals:

- Author declares no conflict of interest
- Study was approved by Research Ethic Committee of author affiliated Institute.
- Study's data is available upon a reasonable request.
- All authors have contributed to implementation of this research.

## References

1. Bray F, Laversanne M, Sung H, Ferlay J, Siegel RL, Soerjomataram I, Jemal A. Global cancer statistics 2022: GLOBOCAN estimates of incidence and mortality worldwide for 36 cancers in 185 countries. *CA: a cancer journal for clinicians*. 2024;74(3):229-263. <https://doi.org/10.3322/caac.21834>
2. Steel G, West C, Nahum A. Dose fractionation in radiotherapy. *In Handbook of radiotherapy physics 2021 Dec 30 (pp. Vol11-123)*. CRC Press.
3. Weiss M, Domschikowski J, Sonnhoff M, Nitsche M, Hoffmann W, Becker-Schiebe M, et al. The impact of palliative radiotherapy on health-related quality of life in patients with head and neck cancer - Results of a multicenter prospective cohort study. *Clinical and Translational Radiation Oncology*. 2023 07;41:100633. <https://doi.org/10.1016/j.ctro.2023.100633>
4. Kancherla KN, Oksuz DC, Prestwich RJD, Fosker C, Dyker KE, Coyle CC, Sen M. The role of split-course hypofractionated palliative radiotherapy in head and neck cancer. *Clinical Oncology (Royal College of Radiologists (Great Britain))*. 2011 03;23(2):141-148. <https://doi.org/10.1016/j.clon.2010.09.006>
5. Gamez ME, Agarwal M, Hu KS, Lukens JN, Harrison LB. Hypofractionated Palliative Radiotherapy with Concurrent Radiosensitizing Chemotherapy for Advanced Head and Neck Cancer Using the "QUAD-SHOT Regimen". *Anticancer Research*. 2017 02;37(2):685-691. <https://doi.org/10.21873/anticancer.11364>
6. Porceddu SV, Rosser B, Burmeister B, Jones M, Hickey B, Baumann K, et al. Hypofractionated radiotherapy for the palliation of advanced head and neck cancer in patients unsuitable for curative treatment - "Hypo Trial" Authors letter of reply. *Radiotherapy and Oncology*. 2008;87(2):309. <https://doi.org/10.1016/j.radonc.2008.03.015>
7. Srivastava A, Adhikari N, Sonkar DR, Singh K, Rath AK. "Christie Regimen" palliative radiotherapy in advanced head-and-neck cancer: A single-center experience. *Journal of Cancer Research and Therapeutics*. 2021;17(1):88-93. [https://doi.org/10.4103/jcrt.JCRT\\_229\\_20](https://doi.org/10.4103/jcrt.JCRT_229_20)



This work is licensed under a Creative Commons Attribution-Non Commercial 4.0 International License.