

# Primary Extranodal Lymphoma – A Three Year Study in a Tertiary Care Centre

Rukmini Bezbaruah<sup>1</sup>, Arpan Choudhury<sup>2</sup>

<sup>1</sup>Department of Oncopathology, Dr. B Borooah Cancer Institute, Guwahati, India. <sup>2</sup>Nemcare Hospital, Guwahati, India.

## Abstract

**Introduction:** Primary extranodal lymphoma ( pENL ) is a group of lymphomas arising from tissues other than lymph nodes. Although the incidence of extranodal non Hodgkin lymphoma (ENL) is increasing worldwide, data is minimal. **Aims and objectives:** To study the prevalence, anatomical distribution, clinical factors, and histological subtypes of extranodal lymphoma. **Materials and methods:** This was a retrospective observational study conducted in the Department of Oncopathology in a regional cancer centre where we retrieved 103 cases of primary extranodal lymphoma ( pENL ) out of 380 cases of lymphoma from the institute's data registry that were diagnosed over a period of three years from January 2017 to December 2019. **Result:** There were 103 patients with primary extranodal lymphoma out of 380 patients with lymphoma, including 68 males and 35 females (M: F = 1.9:1), and the peak incidence occurred during the 4th to 5th decades of life. The age range was 4-80 years, and the mean age was 45.9 years. The median age was 50 years  $\pm$  19.2 years. The commonest site was the gastrointestinal tract (GIT) (31.8%), followed by the breast (15.5%). B-cell lymphoma was more common than T-cell lymphoma. The most frequent histopathological types of B-cell lymphoma were diffuse large B-cell lymphoma (DLBCL) (47%), Burkitt lymphoma (BL) (13%) and marginal zone lymphoma (MZL), (6%). Most of the patients in the pENL group were diagnosed to have Stage I/II lymphoma whereas Stage III/IV was more common in patients with nodal NHL. Most of the patients were treated with chemotherapy following the diagnosis. The most common chemotherapy used was cyclophosphamide, doxorubicin, vincristine, and prednisolone regimen, and rituximab was a part of chemotherapy. **Conclusion:** Primary extranodal lymphomas constitute a diverse group of haematolymphoid malignancies. The diagnosis is a frequent challenge for pathologists, due to their morphological, characteristics and varied clinical presentations. Immunohistochemistry plays a major role in the diagnosis of primary extranodal lymphoma. Compared to the published series, no difference was noted regarding sex predilection or morphology. However, as this was mostly an epidemiological and morphological study, data about the detailed therapeutic outcomes are lacking.

**Keywords:** DLBCL- Lymphoma- extranodal

*Asian Pac J Cancer Care*, 10 (2), 399-403

Submission Date: 12/02/2024

Acceptance Date: 02/21/2025

## Introduction

Primary extranodal lymphoma (pENL) is a group of lymphomas arising from tissues other than lymph nodes. Although the incidence of extranodal non Hodgkin lymphoma is increasing worldwide, data is minimal. Over the last decade, the International Extranodal Lymphoma Study Group (IELSG) has performed several retrospective and prospective trials to clarify the specific features of pENL [1]. In fact, great geographic variability in the overall frequency of extranodal presentations as well as

the distribution of extranodal presentations across various anatomic sites of onset has been described [2]. For the definition, there is no consensus about the staging of primary extranodal lymphomas: the Ann Arbor staging system is currently widely used for describing the extent of the disease [1].

### *Aims and objectives*

To study the prevalence, anatomical distribution,

### Corresponding Author:

Dr. Rukmini Bezbaruah

Department of Oncopathology, Dr. B Borooah Cancer Institute, Guwahati, India.

Email: rukminirbc@gmail.com

clinical factors, and histological subtypes of primary extranodal lymphoma.

## Materials and Methods

### Study design and site

This was a retrospective observational study conducted in the Department of Oncopathology in a regional cancer centre where we retrieved 103 cases of primary extranodal lymphoma (pENL) out of 380 cases of lymphoma from the institute's data registry that were diagnosed over a period of three years from January 2017 to December 2019.

Inclusion criteria: A primary extranodal lymphoma (PENL) was defined by presentation in extranodal organs (organs other than the lymph nodes).

Exclusion criteria: Patients with nodal lymphoma with extranodal involvement were excluded.

### Data gathering

The demographic data, including age, sex, clinical signs and symptoms at presentation, stage of cancer, haemoglobin (Hb) level, platelet count, absolute lymphocyte count (ALC), biochemical parameters such as lactate dehydrogenase (LDH) and treatment modalities, were obtained from the medical records. Staging of lymphoma was done performed by clinical evaluation, computed tomography (CT) scans, and bone marrow aspiration and trephine biopsy as described in the standard recommendations and classified according to the modified Ann Arbor staging system.

### Histopathology

The tissue was routinely processed in 10% formalin, and 5 µm paraffin sections were stained with hematoxylin and eosin. Immunohistochemistry (IHC) was performed using a panel of antibodies depending on the morphology.

The panel of antibodies used for IHC included pan-cytokeratin, leukocyte common antigen CD45, CD3, CD4, CD5, CD7, CD8, CD19, CD20, CD23, CD10, CD15, CD30, CD99, CD56, Bcl2, Bcl6, Tdt, anaplastic lymphoma kinase-1 (ALK-1), cyclinD1, Ki67 and epithelial membrane antigen (EMA), MUM 1, cMyc. A Ventana Benchmark Ultra machine automated staining system was used.

### Peripheral blood, bone marrow aspiration and trephine biopsies

The bone marrow or peripheral blood was collected in an ethylenediaminetetraacetic acid (EDTA) vacutainer. Morphological evaluation was performed on Wright-stained peripheral smears and bone marrow aspirates. All the samples were processed within 24 hours. If the bone marrow aspiration and peripheral smear showed involvement by lymphoma, involvement by lymphoma on morphology was also subjected to IHC for confirmation.

### Statistical analysis

Statistical analysis was performed using Microsoft Excel. The qualitative data are presented as frequencies and percentages, and the quantitative data are presented

as the means or medians.

## Results

There were 103 patients with primary extranodal lymphoma out of 380 patients with lymphoma, including 68 males and 35 females (M: F = 1.9:1), and the peak incidence occurred during the 4<sup>th</sup> to 5<sup>th</sup> decades of life.

Table 1. Patient's Characteristics

Patient's characteristics	Number
Mean platelet volume (cells/mm <sup>3</sup> )	3.6± 1.9 lakhs
Mean Haemoglobin (g/dl )	10.58±2.060
Median LDH	592.06
Immunocompromised status	7/103
Bone marrow involvement	8/103
Bulky disease	13/103
Effusion	2/103
Stage (N)	I 37
Ann Arbor stage	II 44
	IV 22

Table 2. Sites of Extranodal Lymphoma

Sites	No. of cases (percentage)
Gastrointestinal tract	41 (39.8)
Stomach	14 (13.59)
GE Junction	1 (0.9)
Duodenum	3 (2.9)
Jejunum	3 (2.9)
Ileum	7 (6.7)
Colon	2 (1.9)
Caecum	3 (2.9)
Liver	3 (2.9)
Spleen	1 (0.9)
Pancreas	4 (3.8)
Head and neck	7 (6.7)
Tongue	2 (1.9)
Vallecula	1 (0.9)
Nasopharynx	1 (0.9)
Nostril	1 (0.9)
Hard palate	1 (0.9)
Thyroid	1 (0.9)
Kidney	1 (0.9)
Testis	1 (0.9)
Ovary	7 (6.7)
Breast	16 (15.5)
Lung	1 (0.9)
CNS	4 (3.8)
Bone	9 (8.73)
Skin and soft tissue	10 (9.7)
Retroperitoneum	3 (2.9)
Mediastinum	2 (1.9)

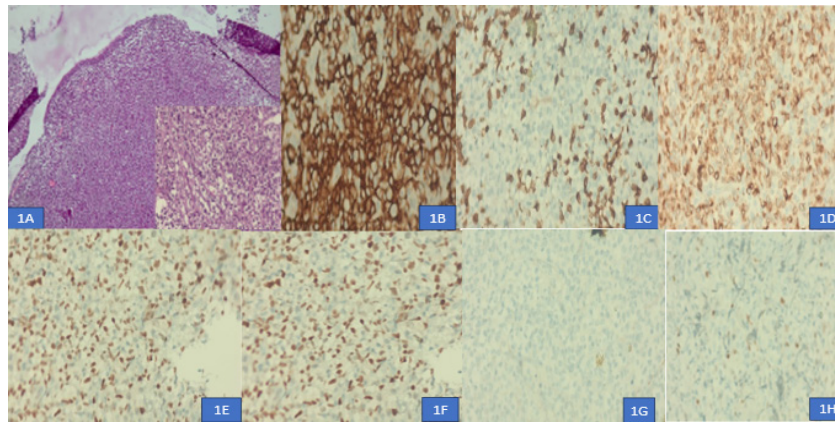


Figure 1. Nasopharyngeal DLBCL (GCB type). 1A, Atypical Lymphoid Cells in Sheets with Overlying Normal Epithelium. 1B, CD 20 positive b cells (400x). 1C, CD 3 positive in surrounding T cells. 1D, BCL2 positivity (400x), 1E, Ki67 positivity 70 % (400x). 1F, BCL 6 positive (400x). 1G, CD 10 negative (400x). 1H, MUM 1 negative (400x)

The age range was 4-80 years, and the mean age was 45.9 years. The median age was 50 years  $\pm$  19.2 years. The detailed patient characteristics are listed in Table 1.

The commonest site was the gastrointestinal tract (GIT) (31.8%), followed by the breast (15.5%) (Table 2). Among the primary gastrointestinal lymphomas, the most common site of involvement was the stomach in 14 cases (34.1%), followed by the ileum in 7 cases (6.7%).

There were 16 patients (15.5%) with breast lymphoma. Right sided breast involvement was greater than left sided breast involvement (56.2% vs 43.7%).

Cutaneous lymphoma comprised 10 (9.7%) patients. Details about the sites of primary extranodal lymphoma are provided in Table 3.

B-cell lymphoma was more common than T-cell lymphoma. The most frequent histopathological types of B-cell lymphoma were diffuse large B-cell lymphoma (DLBCL) (47%), Burkitt lymphoma (BL) (13%) and marginal zone lymphoma (MZL), (6%). Germinal centre (GC) or nongerminal centre (non-GC) phenotypic subtyping was based on immunohistochemistry using the Hans algorithm.

Among the T-cell lymphomas most common were primary cutaneous T-cell lymphoma (NOS) 4 (3.8%).

Bone marrow involvement was noted in 8/103 patients and was detected via both aspiration and biopsy. The most common cases were stage II with 47 cases (45.6%) followed by stage I 21 cases (20.38%) followed by stage IV with 22 cases (21.3%). Refer to Table 1.

There were 14 patients with pediatric extranodal lymphoma in our study. The most common site of presentation was the ileum. The most common histopathological type was Burkitt lymphoma.

## Discussion

According to the literature, primary extranodal lymphoma (PENL) is a rare disease constituting approximately 20-24% of lymphomas. The frequency varies in different parts of the world. The findings of the present study were compared with previously available literature data.

The mean age in the present study was 45.9 years, which was similar to the findings of Vural F. et al. [3] (47 years) and K. S. Dhumure et al. [4] (46.7 years). The male: female ratio was 1.9:1, which is similar to that reported by Wang GB et al [5].

Poorly differentiated or undifferentiated malignancies are always a challenge for pathologists in ascertaining lineage. This is a particularly difficult task when dealing with extranodal sites. Depending on the site and also the histological picture, we used a panel of markers. The differential diagnosis in most of the patients were poorly differentiated tumours and malignant round cell tumours, while in others, we could type it as NHL, but for subtyping, IHC was helpful.

In our study, 88.3% of the patients had B-cell lymphoma and 11.6% had T-cell lymphoma. GI tract involvement in NHL accounts for 30%–40% of cases of extranodal lymphoma. In our study, the GIT was the commonest site for primary extranodal lymphoma (41%), with the stomach being the most affected organ, which is consistent with the findings of Kroll A.D. G. et al [6]. Different histological subtypes of lymphoma can arise in the GIT. In our study, the most common type of GI lymphoma was DLBCL, which was 57% gastric and 21% intestinal in location.

Malt lymphoma represents approximately 35% of primary gastric lymphomas and less than 10% of intestinal lymphomas [1]. Colonization of lymphoid follicles by neoplastic infiltrates may be difficult to differentiate from cases of follicular lymphoma, especially in small and distorted biopsies. The distinction of neoplastic Malt from reactive Malt may be problematic in small biopsies from any extranodal site, and repeat biopsies may be necessary to achieve a diagnosis.

Burkitt's lymphoma patients present with an abdominal mass, and the ileocecal region is most frequently involved [1], which is similar to our study in which we found 29.7% of GI lymphomas to be Burkitt's lymphoma.

In a study by Somanath Padhi et al. [7] the central nervous system was the commonest site (29.5%) of PENL, surpassing the GIT (25%). During our study period, we found only 4 patients (3.88%) with CNS lymphoma.

Table 3. Histopathological Types

Histopathological type	Frequency
Anaplastic Large cell lymphoma	4
B cell lymphoblastic lymphoma	1
Burkitt lymphoma	13
Diffuse large B cell lymphoma- GCB type	30
Diffuse large B cell lymphoma -ABC type	20
Extranodal NK/T Cell lymphoma Nasal type	1
Follicular lymphoma	2
Mantle cell lymphoma	1
Marginal zone lymphoma (Malt lymphoma)	6
Monomomorphic post Transplant lymphoproliferative lymphoma Peripheral T cell lymphoma NOS	1
High grade Non-Hodgkin B cell Lymphoma NOS	12
Plasmablastic lymphoma	2
Primary cutaneous peripheral T Cell lymphoma NOS	4
T Cell Lymphoblastic lymphoma	3
T cell rich large B cell lymphoma	1

The head and neck region has been reported to be the most common site of origin of PENL in various studies from different parts of China (Yang et al., 2011)[8], India (Singh et al. 2003 ) [9] and Japan (Fujita et al. 2009 ) [10]. In our study, most head and neck lymphomas were nodal, and 7% were extranodal lymphomas, which is lower than that reported in other studies. There were two cases each of DLBCL and MZL and one case each of plasmablastic lymphoma and extranodal NK/T-cell lymphoma nasal type (Figure 1).

We reported a case of non-Hodgkin lymphoma of the thyroid with a background of Hashimoto's thyroiditis in a 50-year-old female. Clinically, she complained of difficulty in deglutition. On fine-needle aspiration, the possibility of an NHL was considered, and in the resected specimen, the differential diagnosis included small cell variants of medullary carcinoma, insular carcinoma, and lymphoma. The tumor was negative for calcitonin, but positive for LCA and CD20, indicating lymphoma of the B-cell lineage.

Primary breast lymphoma (PBL) is a rare malignancy that accounts for less than 3% of extranodal lymphomas, 1% of non-Hodgkin's lymphomas (NHLs), and 0.5% of all breast malignancies [11-13]. In this study, there were 16 cases of PBL. The majority of breast lymphomas were DLBCL, one case was follicular lymphoma, and one was mantle cell lymphoma.

Testicular lymphomas account for 5% of all testicular malignancies [14]. In our study, a single patient who was diagnosed with seminoma outside and on review was diagnosed as lymphoma. The tumour was positive for LCA and CD20, suggesting a diagnosis of B-cell NHL. No lymph nodes were enlarged even after 6 months of follow-up, so a secondary lymphoma was ruled out. After a panel of immunohistochemistry markers, we diagnosed it as DLBCL ABC type.

Primary cutaneous lymphomas are defined as non-Hodgkin lymphomas that are present in the skin with no evidence of extracutaneous disease at the time

of diagnosis [15]. In our study, 10% of the patients had primary cutaneous lymphoma, 70% of whom had T-cell lymphoma. Among the CTCLs, the most common was primary cutaneous T-cell lymphoma NOS (PTCL NOS), followed by primary cutaneous ALCL and ALK-positive ALCL. Typically, there is sheet-like growth of tumour cells in the dermis, which may extend into the subcutaneous tissue, without significant epidermotropism. The tumour cells expressed CD30 (> 75% of tumor cells), and CD4, with variable expression of the T-cell antigens CD2, CD3, and CD5.

Most of the patients in the pENL group were diagnosed to have Stage I/II lymphoma whereas Stage III/IV was more common in patients with nodal NHL. Most of the patients were treated with chemotherapy following the diagnosis. The most common chemotherapy used was cyclophosphamide, doxorubicin, vincristine, and prednisolone regimen, and rituximab was a part of chemotherapy.

In conclusion, primary extranodal lymphomas constitute a diverse group of haematolymphoid malignancies. The diagnosis is a frequent challenge for pathologists, due to their morphological characteristics and varied clinical presentations. Immunohistochemistry plays a major role in the diagnosis of primary extranodal lymphoma. Compared to the published series, no difference was noted regarding sex predilection or morphology. However, as this was mostly an epidemiological and morphological study, data about the detailed therapeutic outcomes are lacking.

#### Abbreviations

pENL: Primary extranodal lymphoma, ALK: Anaplastic lymphoma kinase, DLBCL: Diffuse Large B Cell Lymphoma, GIT: Gastrointestinal tract, MZL: Marginal Zone lymphoma

## Acknowledgments

None

## Conflict of Interest

The authors declare no conflict of interest.

## Funding

No specific funding was received for this study

## References

1. Vannata B, Zucca E. Primary extranodal B-cell lymphoma: current concepts and treatment strategies. *Chinese Clinical Oncology*. 2015 03;4(1):10. <https://doi.org/10.3978/j.issn.2304-3865.2014.12.01>
2. Müller AMS, Ihorst G, Mertelsmann R, Engelhardt M. Epidemiology of non-Hodgkin's lymphoma (NHL): trends, geographic distribution, and etiology. *Annals of Hematology*. 2005 01;84(1):1-12. <https://doi.org/10.1007/s00277-004-0939-7>
3. Vural F, Cagiran S, Saydam G, Hekimgil M, Soyer NA, Tombuloglu M. Primary testicular lymphoma. *Journal of the National Medical Association*. 2007 Nov;99(11):1277-1282.
4. Dhumure KS, Hanmante RD, Chopade SW, Bindu RS, Rajharsh D, Hanmante D. Morphological Typing of Extranodal Lymphoma with Immunohistochemical Study..
5. Wang G, Xu G, Luo G, Shan H, Li Y, Gao X, Li J, Zhang R. Primary intestinal non-Hodgkin's lymphoma: a clinicopathologic analysis of 81 patients. *World Journal of Gastroenterology*. 2011 Nov 07;17(41):4625-4631. <https://doi.org/10.3748/wjg.v17.i41.4625>
6. Krol ADG, Cessie S, Snijder S, Kluin-Nelemans JC, Kluin PM, Noordijk EM. Primary extranodal non-Hodgkin's lymphoma (NHL): the impact of alternative definitions tested in the Comprehensive Cancer Centre West population-based NHL registry. *Annals of Oncology: Official Journal of the European Society for Medical Oncology*. 2003 01;14(1):131-139. <https://doi.org/10.1093/annonc/mdg004>
7. Padhi S, Paul TR, Challa S, Prayaga AK, Rajappa S, Raghunadharao D, Sarangi R. Primary extra nodal non Hodgkin lymphoma: a 5 year retrospective analysis. *Asian Pacific journal of cancer prevention: APJCP*. 2012;13(10):4889-4895. <https://doi.org/10.7314/apjcp.2012.13.10.4889>
8. Yang Q, Zhang W, Yu J, Zhao S, Xu H, Wang W, Bi C, et al. Subtype distribution of lymphomas in Southwest China: analysis of 6,382 cases using WHO classification in a single institution. *Diagnostic Pathology*. 2011 08 22;6:77. <https://doi.org/10.1186/1746-1596-6-77>
9. Singh D, Kumar L, Goyal H, et al. Primary extranodal non-Hodgkin's lymphoma in northern India. *Proc Am Soc Clin Oncol*. 2003. 22 2457
10. Fujita A, Tomita N, Fujita H, Motohashi K, Hyo R, Yamazaki E, Hattori M, et al. Features of primary extranodal lymphoma in Kanagawa, a human T-cell leukemia virus type 1 nonendemic area in Japan. *Medical Oncology (Northwood, London, England)*. 2009;26(1):49-54. <https://doi.org/10.1007/s12032-008-9080-0>
11. Franco Pérez F, Lavernia J, Aguiar-Bujanda D, Miramón J, Gumá J, Álvarez R, Gómez-Codina J, et al. Primary Breast Lymphoma: Analysis of 55 Cases of the Spanish Lymphoma Oncology Group. *Clinical Lymphoma, Myeloma & Leukemia*. 2017 03;17(3):186-191. <https://doi.org/10.1016/j.clml.2016.09.004>
12. Thomas A, Link BK, Altekruse S, Romitti PA, Schroeder MC. Primary Breast Lymphoma in the United States: 1975-2013. *Journal of the National Cancer Institute*. 2017 06 01;109(6):djw294. <https://doi.org/10.1093/jnci/djw294>
13. Jia Y, Sun C, Liu Z, Wang W, Zhou X. Primary breast diffuse large B-cell lymphoma: a population-based study from 1975 to 2014. *Oncotarget*. 2018 01 09;9(3):3956-3967. <https://doi.org/10.18632/oncotarget.23285>
14. Renuka I, Rajani M, Sailabala G, Annapurna P, Aparna C. Primary extranodal lymphomas - spectrum of distribution and morphology with immunophenotyping: A 3-year institutional study. *ResearchGate*. 2024 Nov 21;.
15. Willemze R, Cerroni L, Kempf W, Berti E, Facchetti F, Swerdlow SH, Jaffe ES. The 2018 update of the WHO-EORTC classification for primary cutaneous lymphomas. *Blood*. 2019 04 18;133(16):1703-1714. <https://doi.org/10.1182/blood-2018-11-881268>



This work is licensed under a Creative Commons Attribution-Non Commercial 4.0 International License.