

Pigmented Renal Paraganglioma: A Case Report and Review of the Literature

Ezgi Işıl Turhan¹, Özlem Saraydaroğlu², İsmet Yavaşcaoğlu³

¹Department of Pathology, Bursa City Hospital, Bursa, Turkey. ²Department of Pathology, Uludag University Faculty of Medicine, Bursa, Turkey. ³Department of Urology, Uludag University Faculty of Medicine, Bursa, Turkey.

Abstract

Aim: Paragangliomas are rare non-epithelial tumors originating from paraganglia cells in various anatomical regions. Pigmented paragangliomas are more rare. We present the second reported case of kidney-induced pigmented paraganglioma in conjunction with literature. **Case Report:** A 44-year-old female patient with no known systemic disease was evaluated due to palpitations and a mass detected in the right kidney. Surgically, a 6 cm mass localized between kidney middle pole and vena cava inferior was separated from the surrounding tissues. In the sections prepared from the lesion, there were organoid patterned cell islands separated by fibrovascular septa. Brown pigment was evident in most of the tumor cells. Immunohistochemically, tumor cells expressed synaptophysin, chromogranin, NSE. In tumor cells, Mart1 and HMB45 were negative. In the light of all these findings, the case was diagnosed as 'pigmented paraganglioma'. **Discussion:** The most common localizations of paragangliomas are carotid body, vagal body, middle ear, Zuckerkandl organ, mediastinum and retroperitoneum. There are 12 cases of intrarenal paraganglioma reported in the literature. Pigmented paraganglioma originating from the kidney has been reported only once. **Conclusions:** By presenting the second kidney-derived pigmented paraganglioma reported in the literature, we emphasize that the morphological and geographic spectra of these tumors may be large.

Keywords: Paraganglioma- Renal- Pigmented- Melanin- Histopathological

Asian Pac J Cancer Care, 5 (4), 355-358

Submission Date: 08/20/2020 Acceptance Date: 11/09/2020

Introduction

Paraganglia is a structure of neural crest origin, which acts as a chemoreceptor and is specialized from neurosecretory cells [1]. Paragangliomas are rare non-epithelial tumors originating from paraganglia cells in various anatomical regions [2-3]. 80-85% of all paraganglia tumors are adrenal gland-borne pheochromocytomas. The remaining 15-20% is of extra-adrenal origin [4]. Most of the extra-adrenal paragangliomas are head and neck paragangliomas. Up to this point, paragangliomas have been reported in very rare localizations such as uterus [5], kidney [3-6-7], prostate [8]. Pigmented extra-adrenal paragangliomas are more rare. Reported cases are localized in the uterus [5], retroperitoneum, bladder, vertebra, mediastinum [9], orbit [10], heart [11-12-13]. To this day, only one pigmented renal paraganglioma has been reported [3]. We present the second reported case of

kidney-induced pigmented paraganglioma in conjunction with literature.

Case Report

A 44-year-old female patient with no known systemic disease was evaluated due to palpitations and a mass detected in the right kidney. In the upper abdominal computed tomography, there was a mass lesion of 64x44x34 mm with a heterogeneous internal structure which is hypodense in the non-contrasted cross-sections. The mass is in the lower pole anterior part of the right kidney and in close relation with the renal pelvis and ureter. The blood catecholamine levels were normal, blood pressure was 120/80 mmHg. Routine blood hemogram, biochemistry, hormone tests and tumor markers were within normal values. Surgically, a 6 cm mass localized

Corresponding Author:

Dr. Ezgi Işıl Turhan
Department of Pathology, Bursa City Hospital, Bursa, Turkey.
Email: ezgiisilbas@gmail.com

between kidney middle pole and vena cava inferior was separated from the surrounding tissues. Both adrenal glands were normal in surgical inspections.

Materials and Methods

The material was fixed in 10 % neutral formalin. Four micrometer-thick sections were taken from paraffin embedded samples and stained with hematoxylin eosin (H&E). Masson Fontana and Prussian Blue were also applied to several blocks. H&E stained sections were examined and preparations that best represent tumor morphology were selected for immunohistochemical staining. In immunohistochemical staining, pancytokeratin (clone AE1 / AE3 / PCK26), EMA (clone E29), S100 (polyclonal), Mart1 (clone A103), HMB45 (clone HMB45), ki67 (clone 30-9), CD10 (clone SP67), Synaptophysin (clone SP11), Chromogranin (clone LK2H10), NSE (clone MRQ-55) dyes were used. As external controls, skin was used for Panck and EMA, melanomas was used for Mart1 and HMB45, tonsil was used for ki67 and CD10, pancreatic tissue was used for synaptophysin, chromogranine, NSE, s100. Immunohistochemical staining was done with an automatic staining device (Leica Microsystems, Berlin, Germany). PUBMED, Google Scholar and MEDLINE were scanned for literature using the words “pigmented”, “melanotic”, “paraganglioma”, “extraadrenal” and combinations of them.

Results

Macroscopically, the mass was 60x45x40 mm in size, with a smooth surface, round contours, and a dark brown color. The section surface was completely dark brown-black and spongy in appearance (Figure 1).

In the sections prepared from the lesion, there were organoid patterned cell islands separated by fibrovascular septa. The islands consisted of oval and polygonal cells with a hyperchromatic nuclei and granular cytoplasm (Figure 2A). Brown pigment was evident in most of the tumor cells (Figure 2B).



Figure 1. The Section Surface was Completely Dark Brown-black and Spongy in Appearance

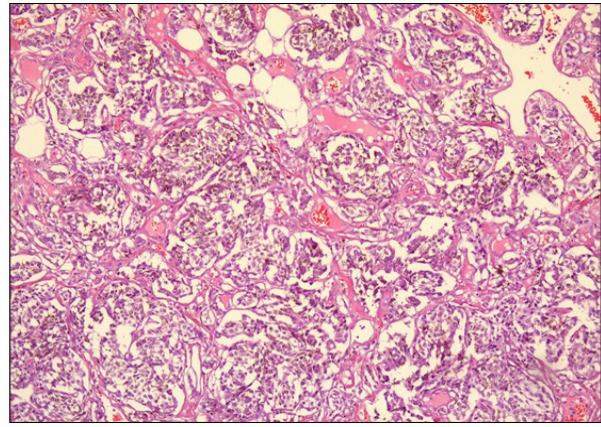


Figure 2 A. The Tumor Cells are Arranged in Zellballen Pattern and have Clear to Finely Granular Cytoplasm (H&E, x400)

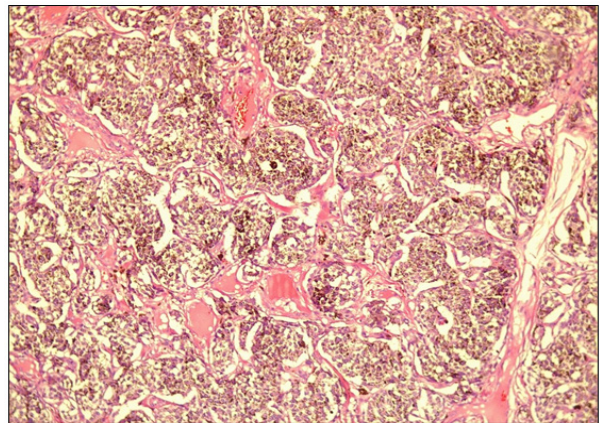


Figure 2 B. Brown Pigment in the Cytoplasm (H&E, x400)

Histochemically, the pigment was not stained with Prussian blue but significant staining was observed with Masson Fontana. Immunohistochemically, tumor cells expressed synaptophysin, chromogranin, NSE. In tumor cells, Mart1 and HMB45 were negative. Sustentacular cells were stained with S100. Ki67 proliferation index was below 5%. Necrosis or mitotic figure was not observed in any area. In the light of all these findings, the case was diagnosed as ‘pigmented paraganglioma’.

Discussion and Review of the Literature

As a result of the literature review, 21 non-adrenal pigmented paraganglioma cases were detected between 1986-2020 (Table 1).

According to the cases reported in the literature, the age range is from 17 to 70, with an average age of 48.3 years. There was a clear female dominance (15 females, 6 males). Tumor sizes range from 3mm to 130mm. Our case is a 44-year-old female patient with a 60 mm tumor.

Extra-adrenal paragangliomas are very rare. The most common localizations are carotid body, vagal body, middle ear, Zuckerkandl organ, mediastinum and retroperitoneum. They have also been reported in several rare localizations.

Table 1. Review of the Literature

	No. of cases	Age/Sex	Localization	Size (mm)	Pigment
Present Case	1	44/f	Kidney	60x45 mm	Melanin/Neuromelanin
Katayama/2019 [21]	1	72/f	Mediastinum	50x35 mm	Melanin/Neuromelanin
Dong/2017 [22]	1	41/f	Thyroid	35x23 mm	Melanin
Zhao/2012 [3]	1	57/m	Kidney	45x45 mm	Neuromelanin
Gonnella/2008 [23]	1	69/f	Heart		Melanin
Yoo/2008 [24]	1	21/f	Brain	49x28 mm	Neuromelanin
Miraldi/2007 [12]	1	69/f	Heart	66x37 mm	Neuromelanin
Dundr/2003 [25]	1	70/f	Bladder	65 mm	Neuromelanin
Reddy/2003 [26]	1	45/m	Vagus nerve	70x60 mm	Neuromelanin
Mikolaenko/2001 [13]	1	40/m	Heart	40 mm	Melanin
Lack/1998 [18]	1	57/f	Retroperitoneum	130 mm	Neuromelanin
Moran/1997 [9]	5	17-56	Vertebrae	20-90 mm	Melanin
		2f	Mediastinum		
		3m	Bladder		
			Retroperitoneum		
Küchemann/1995 [27]	1	45/f	Retroperitoneum	100x50 mm	Melanin
Hofmann/1995 [28]	1	57/f	Mediastinum	110x80 mm	Melanin
Paulus/1989 [10]	1	21/f	Orbit	20x10 mm	Melanin
Tavassoli/1986 [5]	2	31,46/f	Uterus	15mm,3mm	Melanin

There are 12 cases of intrarenal paraganglioma reported in the literature [14]. Pigmented paraganglioma originating from the kidney has been reported only once [3]. Our case is the second known case of pigmented paraganglioma of kidney origin.

It is not known exactly how paraganglioma develops in the kidney, but it is thought to be developed from ectopic adrenal tissues or adrenal residues in the kidney. Another possibility is that neuroendocrine progenitor cells migrating from the neural crest during embryogenesis lead to the development of paraganglioma [3]. Another view regarding intrarenal paragangliomas is renal-adrenal fusion [15]. The renal-adrenal fusion theory was first described by Rokitsansky [16]. According to this view, if a capsule formation cannot be achieved as a result of an error in the retroperitoneal mesenchyma during development, fusion develops between these two organs. This is an important problem for radiologists as well as for pathologists. Adrenal adherent to the kidney can be mixed radiologically with renal masses, causing unnecessary resections. Likewise, a pseudocyst resulting from renal-adrenal fusion may be mistakenly confused with a cystic renal tumor [15]. In our case, both adrenal glands can be clearly demonstrated radiologically.

Renal paragangliomas have been defined in kidney upper pole, hilum and lower pole so far [14]. In our case, the tumor was located in the kidney lower pole and adjacent to the hilum. While paragangliomas of renal pelvis / hilum origin are related to hypertension, paragangliomas with peripheral location are generally not associated with hypertension as in our case [17]. Reported tumor diameters range from 3 to 18 cm. Small lesions can be detected in the early period if they cause symptoms such

as palpitation, sweating, and headache related to hormone secretion [14].

The most important finding in these lesions is the existence of abundant pigment. According to histochemical studies and electron microscopic findings, this pigment is neuromelanin, lipofuskin or true melanin [3]. Neuromelanin has been reported in some pigmented paraganglioma cases [12-18]. Melanin was reported in an article published by Tavassoli in 1986 [5]. Lipofuskin has been reported in retroperitoneal paraganglioma [19]. These pigments accumulating in the tumor are thought to originate from chromaffin cells, chief cells and melanocytes of neural crest origin. Due to the accumulating pigment, the differential diagnosis of pigmented paragangliomas from primary or metastatic malignant melanomas has to be made [20]. Paragangliomas have a growth pattern in the form of classic islands and HMB45 is negative. On the other hand there are pleomorphic cell groups in malignant melanomas, mitotic figures are increased and HMB45 positivity is present [3].

In conclusion, to date, tumors in various spectra such as adrenal cortical adenomas, schwannomas, ganglioneuroblastomas, carcinoid tumors, medullary thyroid carcinomas, dermatofibrosarcoma protuberans have been reported as melanotic or pigmented [20]. Pigmented paragangliomas are very rare. By presenting the second kidney-derived pigmented paraganglioma reported in the literature, we emphasize that the morphological and geographic spectra of these rare tumors may be large.

References

- Mills S. Histology for Pathologists. Paraganglia 4th edition Philadelphia, USA: Lippincott Williams&Wilkins. 2012;:1277-99.
- Lloyd R, Osamura R, Klöppel G, Rosai J. World Health Organization Classification of Tumours of Endocrine Organs. Extra-adrenal paragangliomas 4th ed. Lyon, France: IARC Press. 2017;:190-5.
- Zhao L, Luo J, Zhang H, Da J. Pigmented paraganglioma of the kidney: a case report. *Diagnostic Pathology*. 2012;7(1):77. <https://doi.org/10.1186/1746-1596-7-77>
- Tevosian SG, Ghayee HK. Pheochromocytomas and Paragangliomas. *Endocrinology and Metabolism Clinics of North America*. 2019 Dec;48(4):727-750. <https://doi.org/10.1016/j.ecl.2019.08.006>
- Tavassoli FA. Melanotic paraganglioma of the uterus. *Cancer*. 1986 08 15;58(4):942-948. [https://doi.org/10.1002/1097-0142\(19860815\)58:4<942::aid-cnrcr2820580423>3.0.co;2-t](https://doi.org/10.1002/1097-0142(19860815)58:4<942::aid-cnrcr2820580423>3.0.co;2-t)
- Wu W, Li S, Huang K, Wei Q. Malignant paraganglioma originating from the kidney: a case report and literature review. *Nan Fang Yi Ke Da Xue Xue Bao*. 2011 Jun;31(7):1111-3.
- Yamamoto N, Maeda S, Mizoguchi Y. Malignant paraganglioma arising from the kidney. *International Journal of Clinical Oncology*. 2007 04 27;12(2):160-162. <https://doi.org/10.1007/s10147-006-0632-z>
- Shapiro B, Gonzalez E, Weissman A, McHugh T, Markel S. Malignant paraganglioma of the prostate: case report, depiction by meta-iodobenzylguanidine scintigraphy and review of the literature. *Q J Nucl Med*. 1997 Mar;41(1):36-41.
- Moran CA, Albores-Saavedra J, Wenig BM, Mena H. Pigmented extraadrenal paragangliomas. *Cancer*. 1997 01 15;79(2):398-402. [https://doi.org/10.1002/\(sici\)1097-0142\(19970115\)79:2<398::aid-cnrcr24>3.0.co;2-v](https://doi.org/10.1002/(sici)1097-0142(19970115)79:2<398::aid-cnrcr24>3.0.co;2-v)
- Paulus W, Jellinger K, Brenner H. Melanotic paraganglioma of the orbit: a case report. *Acta Neuropathologica*. 1989 Dec;79(3):340-346. <https://doi.org/10.1007/bf00294673>
- Petramala L, Cotesta D, Filetti S, Letizia C. Pigmented 'black' cardiac paraganglioma in a patient with a novel germ-line SDHD mutation. *Eur J Cardiothorac Surg*. 2009 Jan;35(1):189.
- Miraldi F, Taffon C, Toscano M, Barretta A. Black cardiac paraganglioma in a multiple paraganglioma syndrome. *European Journal of Cardio-Thoracic Surgery*. 2007 Dec;32(6):940-942. <https://doi.org/10.1016/j.ejcts.2007.08.026>
- Mikolaenko I, Galliani C, Davis G. Pigmented cardiac paraganglioma. *Arch Pathol Lab Med*. 2001 May;12(5):680-2. [https://doi.org/10.1043/0003-9985\(2001\)125<0680:PCP>2.0.CO;2](https://doi.org/10.1043/0003-9985(2001)125<0680:PCP>2.0.CO;2)
- Bahar B, Pambuccian SE, Gupta GN, Barkan GA. Renal Paraganglioma: Report of a Case Managed by Robotic Assisted Laparoscopic Partial Nephrectomy and Review of the Literature. *Case Reports in Urology*. 2014;2014:1-6. <https://doi.org/10.1155/2014/527592>
- Ye H, Yoon GS, Epstein JI. Intrarenal ectopic adrenal tissue and renal-adrenal fusion: a report of nine cases. *Modern Pathology*. 2008 09 26;22(2):175-181. <https://doi.org/10.1038/modpathol.2008.162>
- Rokitansky K. A manual of Pathological Anatomy, Vol. Part II, Blanchard: Philadelphia. 1855;:188pp.
- Pickard J, Ross G, Silver D. Coexisting extraadrenal pheochromocytoma and renal artery stenosis: A case report and review of the pathophysiology. *Journal of Pediatric Surgery*. 1995 Nov;30(11):1613-1615. [https://doi.org/10.1016/0022-3468\(95\)90172-8](https://doi.org/10.1016/0022-3468(95)90172-8)
- Lack E, Kim H, Reed K. Pigmented ("black") extraadrenal paraganglioma. *Am J Surg Pathol*. 1998;22:265-9.
- Rupp M, Ehya H. Fine needle aspiration cytology of retroperitoneal paraganglioma with lipofuscin pigmentation. *Acta Cytol*. 1990;34:84-8.
- Belleza G, Giansanti M, Cavaliere A, Sidoni A. Pigmented "Black" Pheochromocytoma of the Adrenal Gland: A case report and review of the literature. *Arch Pathol Lab Med*. 2004;128:e125-128. [https://doi.org/10.1043/1543-2165\(2004\)128<e125:PBPOTA>2.0.CO;2](https://doi.org/10.1043/1543-2165(2004)128<e125:PBPOTA>2.0.CO;2)
- Katayama T, Inoue S, Hirai S. [Pigmented Paraganglioma in the Anterior Mediastinum]. *Kyobu Geka*. 2019 Feb;72(2):108-11.
- Dong Y, Zhang Z, Wang Z, Wang X, Tian Z, Zhang X. Primary Melanotic Paraganglioma of Thyroid Gland: Report of a Rare Case With Clinicopathologic and Immunohistochemical Analysis and a Literature Review. *Clinical Medicine Insights: Pathology*. 2017 01 01;10:117955571668467. <https://doi.org/10.1177/1179555716684670>
- Gonnella C, Messa FC, Confessore P, Greco C. Angiographic evidence of pigmented cardiac paraganglioma. *Journal of Cardiovascular Medicine*. 2008 03;9(3):319. <https://doi.org/10.2459/jcm.0b013e32801411d1>
- Yoo JH, Rivera A, Naeini RM, Yedururi S, Bayindir P, Megahead H, Fuller GN, Suh JS, Adesina AM, Hunter JV. Melanotic paraganglioma arising in the temporal horn following Langerhans cell histiocytosis. *Pediatric Radiology*. 2008 01 15;38(5):571-574. <https://doi.org/10.1007/s00247-007-0734-4>
- Dundr P, Dudorkinová D, Povýšil C, Pešl M, Babjuk M, Dvořáček J. Pigmented Composite Paraganglioma-Ganglioneuroma of the Urinary Bladder. *Pathology - Research and Practice*. 2003 01;199(11):765-769. <https://doi.org/10.1078/0344-0338-00495>
- Reddy CEE, Panda NK, Vaiphei K, Powari M. Pigmented vagal paraganglioma. *The Journal of Laryngology & Otology*. 2003 07;117(7):584-587. <https://doi.org/10.1258/002221503322113102>
- Kchemann K. A rare case of pigmented paraganglioma. *Virchows Archiv*. 1995 08;427(1). <https://doi.org/10.1007/bf00203746>
- Hofmann W, Otto H, Wekel W, Thetter O. Melanotic paraganglioma of the posterior mediastinum. *Virchows Archiv*. 1995 01;425(6). <https://doi.org/10.1007/bf00199354>



This work is licensed under a Creative Commons Attribution-Non Commercial 4.0 International License.