

Giant Renal Cell Carcinoma Surgical Challenges and Life Expectancy: A Real-World Analysis of Serial Cases

Sawkar Vijay Pramod¹, Ferry Safriadi¹, Bethy S. Hernowo², I Nyoman Palgunadi¹

¹Department of Urology, Faculty of Medicine Universitas Padjadjaran, General Hospital Hasan Sadikin Bandung, Indonesia.

²Department of Pathology, Hasan Sadikin Academic Medical Center, Faculty of Medicine Universitas Padjadjaran, Bandung.

Abstract

Giant renal cell carcinoma is a rare case. We reported six cases of giant renal cell carcinoma, which required surgical resection of the tumor, including a 9.900 cm³ of encapsulated neoplasm removal. To our knowledge, this is the largest giant clear cell RCC ever reported in Asia. Cytoreductive nephrectomy without targeted therapy was performed in all cases. The most common type in all cases was clear cell carcinoma. From six cases, four patients died during follow-up of more than 6 months. The number of cases that died in our case was related to poor preoperative status performance, while one of the patients had a histopathological sarcomatoid cell result with a poor prognosis. We should consider performing cytoreductive nephrectomy in younger patients, clear-cell histology, good performance status, limited metastatic burden, 3 or less International Metastatic RCC Database Consortium (IMDC) risk factors, responding to presurgical therapy, preferably in high-volume centers. Cytoreductive nephrectomy is not for every patient, and it's associated with longer survival in well-selected patients.

Keywords: Cytoreductive nephrectomy- giant renal cell carcinoma- life expectancy- surgery

Asian Pac J Cancer Care, 6 (3), 339-342

Submission Date: 02/11/2021 Acceptance Date: 05/28/2021

Introduction

Giant renal cell carcinoma, a tumor with a volume of more than 1000cc, is rare. Giant renal cell carcinoma is an unusual case because of its slow growth rate and the development of imaging techniques [1-3]. A case report by Oviedo et al. found that the largest RCC in the world at 28 x 25 x 15 cm and a total volume of 10,500 cm³ was successfully resected. They also stated that surgery offers several options for patients with RCC. Surgical treatment with or without targeted therapy came with varied outcomes [4]. We presented six cases of giant renal cell carcinoma that required surgical resection of the tumor in Hasan Sadikin Hospital Bandung. Surgical treatment with or without targeted therapy came with varied outcomes.

Case Report

The study was conducted on six cases of giant renal cell carcinoma who required surgical resection of the tumor at Hasan Sadikin General Hospital - Indonesia. Patient characteristics and follow-up can be seen in

Table 1. All diagnosis was made based on the history of illness, physical examination, CT-Scan, and confirmed by histopathological examination (Table 1 and Figure 1). Cytoreductive nephrectomy was performed in all cases. Based on histological examination, clear cell carcinoma was the most common type found in this study. We found that 5 cases in our study were of clear cell carcinoma type and another case with sarcomatoid cells. Follow-up was performed 12 months after surgery to find a metastatic progression. We found that 2 of our patients had no complaints and morbidity after 6 months of surgery.

Case 1 A 50-years-old female patient presented with a chief complaint of pain in the left flank with a visual analog scale (VAS) 3-4 and a history of red-colored urine. Physical examination showed a palpable mass at the right flank, and ECOG score performance status (PS) was 2. We found a solid and non-homogenous mass of the upper and lower left abdomen from abdominal and pelvic CT Scan, originating from the left kidney, which

Corresponding Author:

Dr. Sawkar Vijay Pramod

Department of Urology, Faculty of Medicine Universitas Padjadjaran, General Hospital Hasan Sadikin Bandung, Indonesia.

Email: doktervj@yahoo.co.id

was suggestive of cT4N1M0 renal cell carcinoma with a volume of 3.240 cm³ (12x15x18 cm). We performed a cytoreductive nephrectomy and pelvic lymph node dissection with splenectomy. Three months after the procedure, we performed a follow-up CT scan. The results showed recurrent nodules appear as multiple lymphadenopathies at the left kidney, and pathological biopsy showed clear cell carcinoma. The patient died 12-month after the procedure.

Case 2 A 45-year-old female patient complained of red-colored urination and pain in her right flank with VAS 3-4. Physical examination showed a palpable mass at the right flank, and ECOG score performance status was 2. On an abdominal CT scan, we observed a large mass at the lower pole of the right kidney extending to the right abdominal cavity. The patient was diagnosed with cT4N1M0 right kidney tumor with a volume of 5.168 cm³ (19x17x16 cm). We performed a right cytoreductive nephrectomy and lymph node dissection on the patient. During 12 months follow-up, the patient reported no complaint, and imaging showed no recurrence. The histopathology of the tumor showed clear cell carcinoma.

Case 3 A 66-years-old male presented with a chief complaint of pain on the left flank with VAS 3-4 and red-colored urine since 5 months ago. Physical examination showed a palpable mass at the right flank and ECOG score performance status was 2. CT scan revealed a cT4N1M0 right kidney tumor, the volume was 2.090 cm³ (19x11x10cm), with suspected infiltration into the adrenals. A right cytoreductive nephrectomy, adrenalectomy, and lymph node dissection were performed. On the 3 months follow-up, chest X-ray and lab results were within normal limits. Ultrasound examination showed nodules that appear as multiple lymphadenopathies near the inferior vena cava, porta hepatis, paraaortic, and left pararenal sites. The histopathological result was sarcomatoid renal cell carcinoma. The patient died 6 months after the procedure.

Case 4 A 58-years-old male patient presented with a chief complaint of low back pain with VAS 3-4. Physical examination showed a palpable mass at the left flank, and ECOG score performance status was 3. The abdominal CT Scan with contrast revealed a left kidney tumor and suspected metastasis. The patient was diagnosed with a left kidney tumor cT4N1M1 (lung) with 1008 cm³ (18x14x4 cm) volume that had infiltrated the pancreatic tail, spleen, and colon descendent. During the operation, a left kidney measuring 18 x 14 x 4 cm was found very adherent to the spleen, pancreas, diaphragm, and descending colon with metastasis to the lymph nodes. We performed cytoreductive nephrectomy, retroperitoneal lymph node dissection, and splenectomy. The histopathological result showed clear cell carcinoma with lymph node spreading. The patient died 6-month after the procedure.

Case 5 A 62-years-old man with a left abdominal lump that had continued to grow for the last five years accompanied by pain with VAS 4. Physical examination showed a palpable mass at the right flank, and ECOG

score performance status was 1. CT scan detected an inhomogeneous isodense lesion with calcification in the left kidney. The patient was diagnosed with a left kidney tumor cT4N0M0. Intraoperative findings showed a left kidney measuring 22 x 25 x 18 cm and weighing 5 kilograms. This tumor was the largest giant RCC presented in our cases. We performed a left cytoreductive nephrectomy on the patient. The histopathological result showed renal cell carcinoma. There was no complication during the 12 months follow-up [5].

Case 6 A 40-years-old man presented with a complaint of a right abdominal lump that had continued to grow for the last six months and dull pain with VAS 3-4. Physical examination showed no abnormalities, and ECOG score performance status was 2. CT scan detected an inhomogeneous isodense lesion with calcification in the

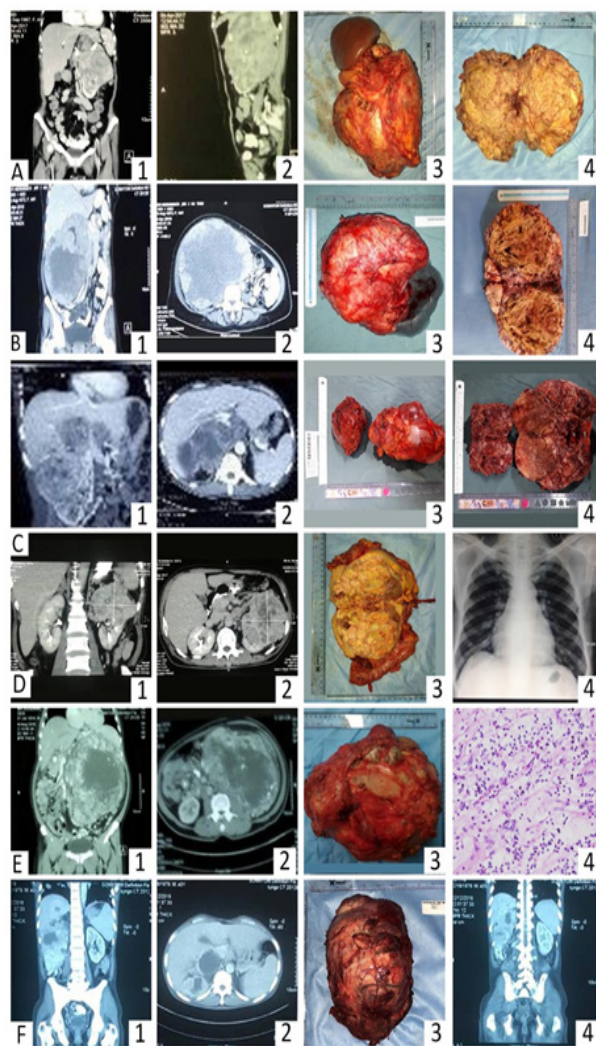


Figure 1. Computed Tomography (CT) and Post Operative Renal Mass; A. Case 1. Patient with Left Kidney Tumor cT4N1M0; B. Case 2. Patient with Right Kidney Tumor cT4N1M0; C. Case 3. Patient with Right Kidney Tumor cT4N1M0; D. Case 4. Patient with Right Kidney Tumor Left Kidney Tumor cT4N1M1 (Lung metastases); E. Case 5. Patient with Left Kidney Tumor cT4N0M0 with histopathology pattern shows clear cell carcinoma; F. Case 6. Patient with Right Kidney Tumor cT4N0M1 (Hepatic and lung metastases)

Table 1. Patient Characteristics and Follow Up

No	Patient	Volume	Diagnosis	Surgical	Follow up	Histopathology	Survival
1	Female 50 years old ECOG 2	3.240 cm ³ (12x15x18 cm)	Left Kidney Tumor cT4N1M0	Cytoreductive Nephrectomy + Lymph node dissection + splenectomy	Three months postoperative CT Scan showed recurrent nodules appear as multiple lymphadenopathies at left kidney, patient died 12 months after procedure	Clear cell carcinoma	12 months
2	Female 45 years old ECOG 2	5.168 cm ³ (19x17x16 cm)	Right Kidney Tumor cT4N1M0	Cytoreductive Nephrectomy + Lymph node dissection	No complaint and no recurrence during 12 months	Clear cell carcinoma	> 12 months
3	Male 66 years old ECOG 2	2.090 cm ³ (19x11x10cm)	Right Kidney Tumor cT4N1M0	Cytoreductive Nephrectomy and Lymph node dissection + adrenalectomy	Three months follow up showed chest x-ray and lab results were within normal limits. Ultrasound examination showed nodules appear as multiple lymphadenopathies near the inferior vena cava, porta hepatis, paraaortic, and left pararenal sites The patient died 6 months after the procedure	Sarcomatoid cell	6 months
4	Male 58 years old ECOG 3	1008 cm ³ (18x14x4 cm)	Left Kidney T umor cT4N1M1 (Lung Metastases) IMDC 4	Cytoreductive Nephrectomy, retroperitoneal, lymph node dissection, splenectomy	Died 6 months after the procedure	Clear cell carcinoma with lymph node spreading	6 months
5	Male 62 years old ECOG 1	9.900 cm ³ (22x25x18cm)	Left Kidney Tumor cT4N0M0	Cytoreductive Nephrectomy	No complaint and recurrence during 12 months	Clear cell carcinoma	> 12 months
6	Male 40 years old ECOG 2	2470 cm ³ (19x13x10 cm)	Right Kidney Tumor cT4N0M1 (Lung and liver Metastases) IMDC 3	Cytoreductive Nephrectomy	Died two weeks after the procedure	Clear cell carcinoma	2 weeks

right kidney. We also found metastases on the liver and lung. The patient was diagnosed with a right kidney tumor cT4N0M1 (liver and lung metastases) and underwent a right cytoreductive nephrectomy. Intraoperative findings showed a right kidney measuring 19 x 13 x 10 cm and weighing 1326 grams. The histopathological result showed clear cell carcinoma. The patient died two weeks after the procedure.

Discussion

The “giant” term is not a standard term. But the term giant, huge and large renal cell carcinoma has been mentioned in several journals. Some of the smallest and largest volumes were reported. However, the cut-off point to determine whether the volume is considered big or small has not been established. From the published study, the largest volume found was 10.500cm³, and the smallest weighed for 1970 grams [1]. Renal cell carcinoma itself can be metastatic or nonmetastatic.

The diagnosis in this patient was based on the findings on the history taking, physical examination, and advance CT. The classic triad in the form of flank pain, hematuria, and palpable abdominal mass was found. Standard imaging tests to detect and confirm the diagnosis of kidney malignancy include ultrasonography (USG), computed tomography (CT) scans, and magnetic resonance imaging (MRI) [1]. In general, kidney malignancy can

be diagnosed accurately only by using imaging tests. CT scans are the most accurate investigation modality to determine whether the tumor has metastasized to the lungs or lymph nodes. However, CT scans are not routinely done in the evaluation of bone and brain metastases [1-2].

In a condition where cytoreductive nephrectomy is not an option, targeted therapy can also be used [4]. In our six cases, we performed cytoreductive nephrectomy without targeted therapy. Four patients died in 2 weeks, 6 months, and 12 months post-operative. One patient had a metastatic nodule at 3 months follow-up, and 2 patients had no complaint after 12 months follow-up. In our cases, we should have done a selective cytoreductive nephrectomy, but we immediately took action because all patients came complaining of pain with Visual Analogue Score (VAS) 3-4.

From six cases, four died during follow-up of more than 6 months. The number of cases that died in our case was related to poor preoperative status performance, while one of the patients had a histopathological sarcomatoid cell result with a poor prognosis. We should consider performing cytoreductive nephrectomy in younger patients, clear-cell histology, good performance status, limited metastatic burden, 3 or less International Metastatic RCC Database Consortium (IMDC) risk factors, responders to presurgical therapy, preferably in high-volume centers.

In conclusion, Treatment of giant renal cell carcinoma

can be challenging. In patients with poor karnofsky and IMDC score, we should perform targeted therapy. However, targeted therapy in our cases could not be done because the national health insurance did not cover it.

Cytoreductive nephrectomy is not for every patient, and it is associated with longer survival in well-selected patients.

Funding

This research received no specific grant from any funding agency in the public, commercial, or not-for-profit sectors.

Declaration Of Conflicting Interests

The Author(s) declare(s) that there is no conflict of interest.

Ethic Considerations

This study has been following COPE and received Ethics Approval from the Ethics Committed, Faculty of Medicine, Universitas Padjadjaran, Bandung, Indonesia prior to the study being conducted. The information and images used have obtained ethical approval and from the patient

References

1. Chueh K, Yeh H, Li C. A huge renal cell carcinoma: Case report and literature review. *Urological Science*. 2013 06;24(2):58-60. <https://doi.org/10.1016/j.urols.2013.05.001>
2. Wu M, Liaw C, Chen Y, Tian Y, Hsueh S, Jenq C, Fang J, Yang C. A giant sarcomatoid renal cell carcinoma. *Nephrology Dialysis Transplantation*. 2007 01 05;22(3):952-953. <https://doi.org/10.1093/ndt/gfl746>
3. Li P, Jahnke J, Pettit AR, Wong Y, Doshi JA. Comparative Survival Associated With Use of Targeted vs Nontargeted Therapy in Medicare Patients With Metastatic Renal Cell Carcinoma. *JAMA Network Open*. 2019 06 14;2(6):e195806. <https://doi.org/10.1001/jamanetworkopen.2019.5806>
4. Oviedo RJ, Robertson JC, Whithaus K. Surgical challenges in the treatment of a giant renal cell carcinoma with atypical presentation: A case report. *International Journal of Surgery Case Reports*. 2016;24:63-66. <https://doi.org/10.1016/j.ijscr.2016.05.010>
5. Pramod SV, Safriadi F, Hernowo BS, Dwiyana RF, Palgunadi IN. A case report of one of the largest (9900 cm³) clear cell renal carcinoma removed in Asia. *Urology Case Reports*. 2020 09;32:101208. <https://doi.org/10.1016/j.eucr.2020.101208>



This work is licensed under a Creative Commons Attribution-Non Commercial 4.0 International License.