

Reliability of Oncoplastic Breast Conserving Surgery for Management of Early Breast Cancer in Yemeni Patients

Jamila A. Alsanabani¹, Butheinah A. Al-Sharafi², Afif Al-Nabhi³

¹Department of General Surgery, Plastic & Reconstructive Surgery Unit, Faculty of Medicine & Health Sciences, Sana'a University, Sana'a, Yemen. ²Department of Medicine, Sana'a University, Sana'a, Yemen. ³National oncology center, Department of Medicine, Sana'a University, Sana'a Yemen.

Abstract

Background: Oncoplastic breast conserving surgery is limited in treatment of Yemeni breast cancer. The aim of this study is to evaluate the reliability and safety of oncoplastic breast surgery in Yemeni patients with early breast cancer. **Material & Methods:** Patients with early breast cancer who underwent oncoplastic breast conserving surgery from July 2014 to July 2020 were included in this retrospective study. Data on the patient's demographic, tumor characteristics, the type of oncoplastic technique performed, surgical margin involved, re-excision rate, complications, satisfaction, follow up and local recurrence rate were included to evaluate the results. **Results:** A total of 50 breast cancer patients underwent oncoplastic surgery by using different techniques. Volume displacement technique was the commonest technique used in 92% of the patients (local glandular flap in 64%, reduction mammoplasty in 22%, Grissoti flap in 4% and bat-wing in 2%) While the volume replacement (Latissimus dorsi flap) technique was used in 8 % of the patients with small breasts. 70% of the patients were less than 40 years old. The mean tumor size was 3.4cm. Most of the tumors (84%) was invasive ductal carcinoma. The overall postoperative complication was 14% [wound infection (4%), wound dehiscence (8%) and fat necrosis (2%)]. Re excision rate was 12% and complete mastectomy was performed for 2 patients. Patient satisfaction was 96%. Local recurrence rate was 4% with mean follow up of 23.1 (SD:16) months. **Conclusion:** The oncoplastic breast conserving surgery is reliable and safe with good oncological and aesthetic outcomes for treatment of early breast cancer in Yemeni patients.

Keywords: Oncoplastic breast conservation surgery- volume displacement- volume replacement- breast cancer

Asian Pac J Cancer Care, 7 (1), 15-20

Submission Date: 08/07/2021 Acceptance Date: 01/03/2022

Introduction

Breast conserving surgery (BCS) together with radiotherapy has been accepted as standard treatment of early stages of breast cancer [1-3]. Conventional BCS in the treatment of early stage breast cancer has been successful in the few decades, but still many cases ended up with aesthetically non-pleasing results [4, 5]. The poor cosmetic cases had been reported up to 30% in some of the series. These aesthetically non-pleasing results had been associated especially with central, medial tumor location, large tumor size, and radiotherapy [6-8].

Oncoplastic breast surgery was started due to a need to maintain the aesthetic outcomes after surgery while still maintaining the oncological principles. Although safe and

adequate tumour resection will always be a primary goal to breast surgical oncologists, better aesthetic outcomes that will not stigmatize the patients after surgery is required [9].

Oncoplastic breast surgery combines principles of oncology and plastic surgery to achieve oncological and aesthetically pleasant results [10]. Also oncoplastic breast surgery expands the indications for breast conserving allowing the resection of much larger tumour in relation to breast size. Oncoplastic breast surgery is an option for the surgical treatment of tumors larger than 4 cm and locally advanced cancers after responding to chemotherapy, where in the past mastectomy was the only option [11, 12].

The surgical techniques used in oncoplastic breast

Corresponding Author:

Dr. Jamila Alsanabani

Department of surgery, plastic & reconstructive unit, faculty of medicine & health sciences, Sana,a university, Yemen.

Email: jsanabani2015@gmail.com

surgery for breast conservation can be largely divided in 2 categories, either volume displacement (VD) or volume replacement (VR) [13]. The choice of the appropriate technique is based on patient and tumour characteristics because the outcomes of the surgery may depend on the type of technique. This technique involves mobilizing local glandular flaps and redistributing them to the resection defect, or it relies on harvesting autologous tissue from a remote site and transferring the flap into the resection defect.

Materials and Methods

Patients with early breast cancer (stage 1, 11) who underwent oncoplastic breast conserving surgery from July 2014 to July 2020 were included in this retrospective study. Data on patient demographics, tumor characteristics, the type of oncoplastic technique performed, surgical margin involved, re-excision rate, complications, satisfaction, follow up and local recurrence rate were included to evaluate the results. All patients underwent these techniques according to their desire. These patients were operated on by a single surgeon. Aesthetic satisfaction was verbally obtained from the patients one month postoperative. Patients were followed either phone call or in outpatient's clinic. All patients received adjuvant radiotherapy as a standard component of breast conserving therapy and also continued chemotherapy after surgery as decided by the MDT.

Statistical analysis

The data was entered and analyzed using SPSS version 26 and presented using tables and graphs. The qualitative variables were expressed by frequency and percentage, and the quantitative variables were described by range, mean, standard deviation (SD).

Results

A total of 50 breast cancer patients underwent oncoplastic breast surgery by using different techniques. The mean age was 38.5 (SD: 9.5) years old, (Range 17

Table 1. Age Group of the Patients (n=50)

Age (year)	No.	%
< 30	9	18
31 - 40	26	52
41 - 50	9	18
51 - 60	5	10
> 60	1	2

to 65) years old. About 70% of the patients less than 40 years old (Table 1).

The right side of the breast was involved as the left side (50% in each side). The anatomical site of the tumour within the breast varied between UOQ (42%), LOQ (10%), UIQ (12%), LIQ (10%), retro-areola (4%), UQ (16%) and LQ (4%). The mean tumour size was 3.4 (SD:1.1) cm. Ranging from 2 to 7 cm, with 60% of the patients presenting with palpable axillary lymph nodes. Only two patients (4%) underwent neoadjuvant chemotherapy to decrease the size of the tumor.

Volume displacement (VD) was the commonest technique used in 46 patients (92%), while volume replacement (VR) in 4 patients (8%). The volume displacement techniques included local glandular (rotation advancement) flaps in 32 patients (64%), reduction mammoplasty in 11 patients (22%), Grissotti flap in 2 patients (4%) and bat-wing in one patient (2%), while the volume replacement technique with latissimus dorsi flap was in 4 patients (Table 2).

Most of the patients (84%) had invasive ductal carcinoma and 98% of the patients had lymph node involvement (Figure 1).

Overall postoperative complications occurred in 14% of the patients, wound infection in 2 patients (4%) when managed conservative, wound dehiscence in 4 patients (8%). only 2 patients needed re-suturing and fat necrosis occurred in one patient (2%) (Table 3).

Re-excision was performed in 6 patients (12%) who had a close margin (< 2 mm). Two patients (4%) had an involved margin and needed a completion mastectomy.

Forty - eight patients (96%) were satisfied with the

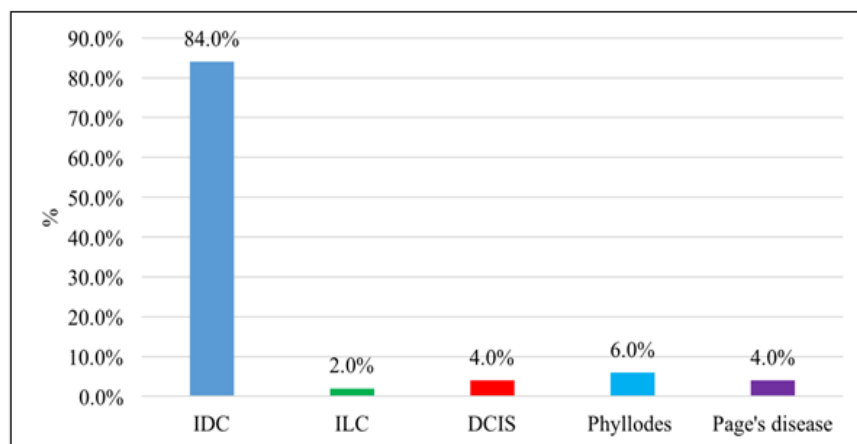


Figure 1. Pathological Types of the Tumor (n=50), (IDC, invasive ductal carcinoma; ILC, invasive lobular carcinoma; DCIS, ductal carcinoma In Situ)

Table 2. Types of OPS Used in the Study (n=50)

Surgical procedure	No.	%
Volume displacement	46	92
Local glandular flap	32	64
Therapeutic mammoplasty (reduction)	11	22
Grisotti flap	2	4
Bat-wing tech.	1	2
Volume replacement (LDF)	4	8

results while tow patients (4%) were not satisfied.

The mean follow up of the patients was 23.1 (SD:16) months (range 5 - 60) months. Two (4.7%) patients had local recurrence, one at 24 and another 15 months after surgery. Seven patients were lost for follow up.

Discussion

Oncoplastic breast conserving surgery should be recommended versus standard breast conserving surgery for the treatment of operable breast cancer in adult women who are suitable candidates for breast conserving surgery [14].

Youssef et al., (2018) in their study recommended oncoplastic breast surgery as the standard of treatment in early breast cancer and in selected cases with locally advanced breast cancer showed good response to neoadjuvant chemotherapy [15].

Our study revealed that oncoplastic breast conserving surgery was useful in patients with early breast cancer such as patients with large tumor to breast size ratio or patients with macromastia. Most of our patients (92%) had volume displacement techniques. The selection of

the type of oncoplastic technique in managing breast cancer depends on the tumor size to breast size ratio, where the mean tumor size in our study was 3.4 cm (ranging 2 - 7cm). So different techniques were used in our study. Among the volume displacement techniques 64% of our patients had wide local excision with local glandular flap and nipple areola complex (NAC) re - centralization. This technique is simple, safe and maintains the shape of the breast (Figure 2). When the volume to be excised was larger in a large breast a therapeutic mammoplasty technique was performed. This technique reduced the size of large breast, improved the margins of the tumor resected, in addition it preserved the shape of the breast. It gave good aesthetic results especially when reduction mammoplasty was done also for the contralateral side for symmetrization (Figure 3). The therapeutic mammoplasty in our study included a Grisotti flap for central tumors, superior pedicle mammoplasty for lower pole tumors and an inferior pedicle mammoplasty for upper pole tumors. Clough et al., (2003) reported therapeutic mammoplasty as a good technique for cosmetic outcomes allowing wider margins of tumor resection making it oncologically favourable [16]. Yazar and colleagues (2018) believed that the oncoplastic approach to breast conserving surgery in patients with macromastia had many advantages as

Table 3. Post-operative Complications (n=50)

Variable	No. Of patients	%
No	43	86
Infection	2	4
Wound dehiscence	4	8
Fat necrosis	1	2

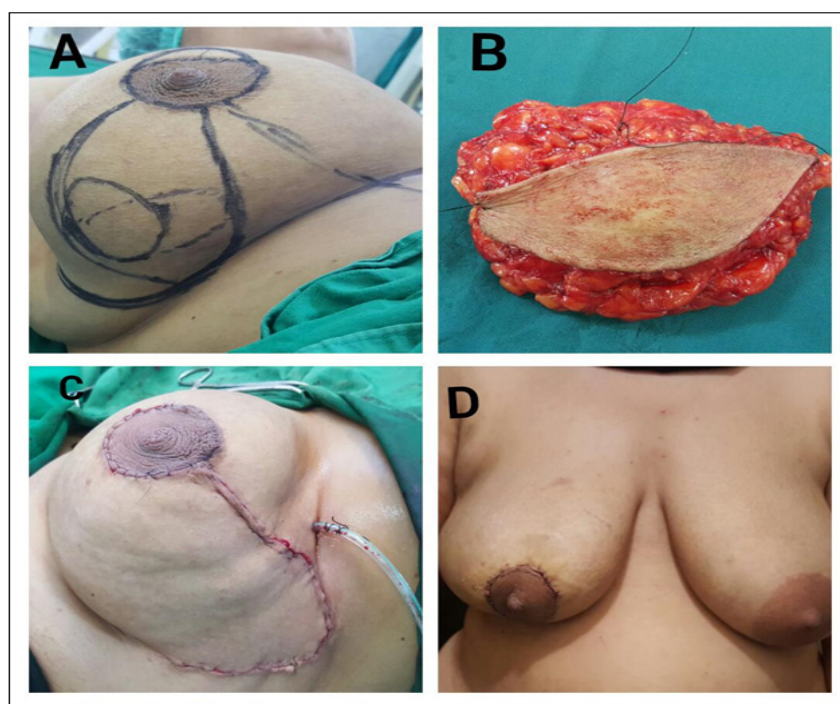


Figure 2. Oncoplastic Technique Using a Local Glandular Flap (A), Preoperative View; (B), The Resected Tumor; (C), Intraoperative View; (D), 4 Weeks Postoperative View.

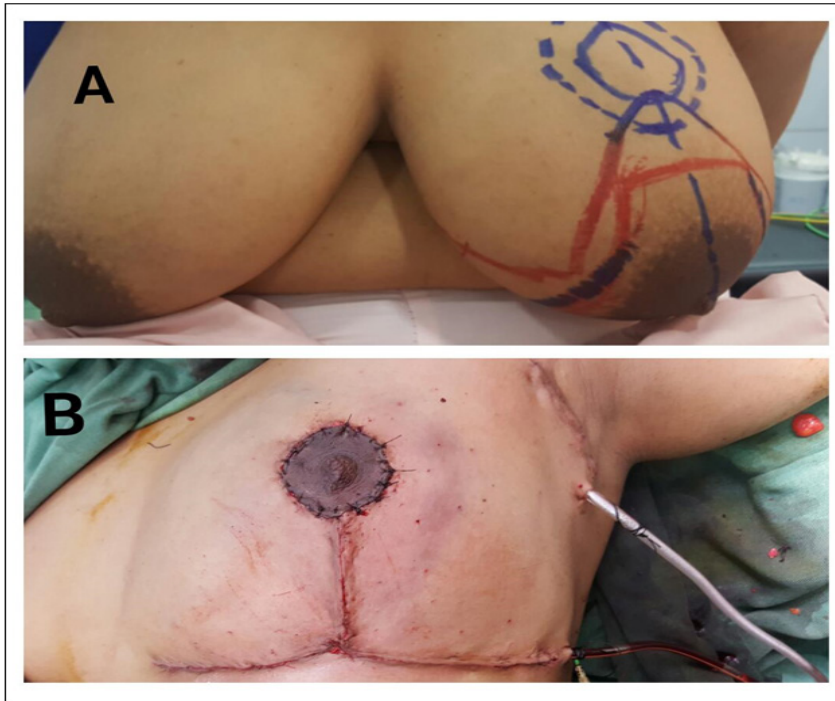


Figure 3. Oncoplastic Technique by Using Inferior Pedicle Reduction Mammoplasty, (A), Preoperative View; (B), Intraoperative View

it improved the final aesthetic results by maintaining the natural breast contours, especially in large tumors maintaining the breast contour after resection has proven to be challenging [17]. It has been reported in earlier studies that more than 15 - 20 % reduction in the breast volume depending on tumor location, can decrease the aesthetic outcome of the surgery significantly [2, 18]. This volume was reported to be low as 5 % for medial tumor location

[19]. When the breast size in our patients was small a volume replacement with latissimus dorsi myocutaneous flap (8%) was performed to maintain a good safety margin with good cosmetic results (Figure 4).

Preoperative tumor size, tumor location and intra-operative margin assessment are mandatory to obtain clear margin while preserving breast contour. There is an international agreement that 'no tumor on ink' is an

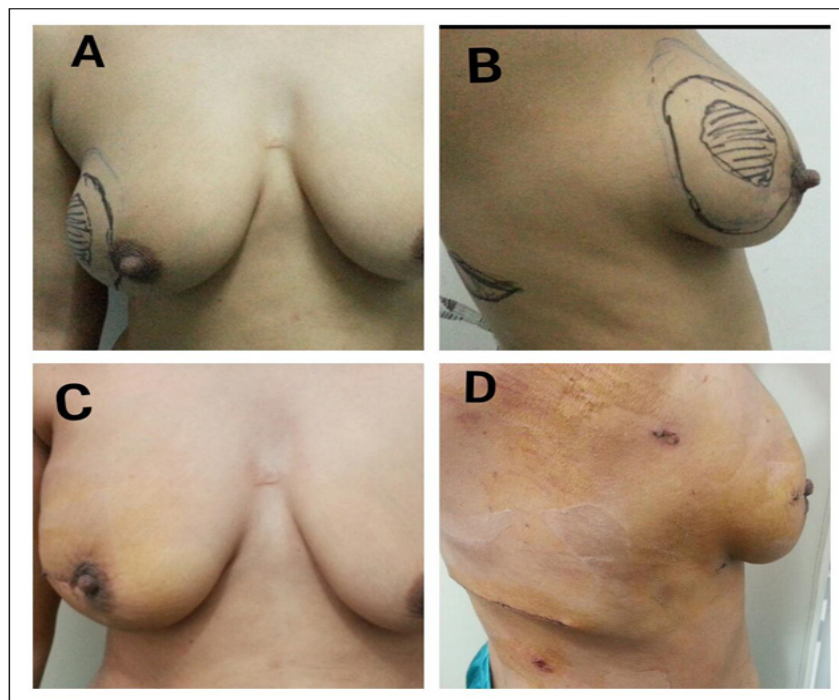


Figure 4. Oncoplastic Technique of VR with Latissimus Dorsi Flap (A, B), Preoperative View; (C, D), Postoperative View.

acceptable resection margin in invasive breast cancer [20, 21] even though a recent meta-analysis [22] suggested that a 2 mm margin may be more adequate. Andre and colleagues, (2020) reported, no advantage for resection margins wider than 2 mm [23]. In our study we assessed the surgical margins blindly by excising more tissue around the tumor due to lack of frozen section analysis in our hospitals. Our results revealed that 6 patients (12%) had a close margin (< 2 mm) and 2 patients (4%) had a positive margin as a postoperative histopathology results. Re - excision and mastectomy were performed in the patients with close and positive margins respectively. These results are similar to another study where ten patients (14%) had positive margins, for which seven (10 %) patients required re - excision and three patients required mastectomy [24].

Studies reported that the average complications rate of (16%) associated with oncoplastic breast surgery are acceptable [25]. The overall complications in our study was (14%), including wound infection (4%) treated conservatively, wound dehiscence (8%), only 2 patients treated with re-suturing and fat necrosis (2%). In comparison another study stated that the common complications following oncoplastic techniques especially volume displacement technique were delayed wound healing (3 - 15%), fat necrosis (3 - 10%) and infection (1 - 5%) [26].

In our study, the patient satisfaction regarding the aesthetic outcomes was 96%. This is similar to another study which revealed that all patients were aesthetically satisfied and were also relieved from their symptoms related to macromastia [17]. Dahlback and colleagues, (2016) stated a poor patient satisfaction in Standard breast conserving surgery when more than 20% of the preoperative breast volume was excised [27].

The follow up of our patients ranged from 5 to 60 months, in which tow patients (4.7%) had local recurrence. One of them occurred 24 months after the primary surgery and the other 15 months after the primary surgery. This is similar to another study which reported 6.8% local recurrence in a 540 consecutive patients who underwent oncoplastic breast surgery for cancer with a median follow up 49 months (6 - 262 months) [28]. Also another study revealed that for cancer recurrence rate there was no significant difference between oncoplastic surgery and standard breast conserving surgery, sooncoplastic breast surgery is a safe and a useful option in suitable patients [29].

Our study is not without limitations. It is a single center study with a small sample size. Patient's ignorance and fear from local recurrence caused most patients to deny oncoplastic surgery, despite breast cancer affecting a younger age in Yemen, who would usually seek to preserve the breast versus mastectomy. Also lack of frozen section analysis limits oncoplastic breast surgery in many cases. In addition most of the patients present in a late stage.

In conclusion, our results confirm that oncoplastic breast conserving surgery is reliable for surgical treatment of early breast cancer in Yemeni patients. It is safe with good oncological and aesthetic outcomes. So it is

important to choose the proper technique for each patient.

Acknowledgements

The authors wish to thanks Dr. Farouk Al - Qadasi for his assistance with the statistical analysis.

Funding Statement

The authors did not receive any specific funding.

Ethics Committee

The study was approved by Sana'a University Medical School Research Committee.

References

1. Bartelink H, Horiot J, Poortmans PM, Struikmans H, Van den Bogaert W, Fourquet A, Jager JJ, Hoogenraad WJ, Oei SB, Wárlám-Rodenhuis CC, Pierart M, Collette L. Impact of a Higher Radiation Dose on Local Control and Survival in Breast-Conserving Therapy of Early Breast Cancer: 10-Year Results of the Randomized Boost Versus No Boost EORTC 22881-10882 Trial. *Journal of Clinical Oncology*. 2007 08 01;25(22):3259-3265. <https://doi.org/10.1200/jco.2007.11.4991>
2. Pukancsik D, Kelemen P, Újhelyi M, Kovács E, Udvarhelyi N, Mészáros N, Kenessey I, Kovács T, Kásler M, Mátrai Z. Objective decision making between conventional and oncoplastic breast-conserving surgery or mastectomy: An aesthetic and functional prospective cohort study. *European Journal of Surgical Oncology (EJSO)*. 2017 02;43(2):303-310. <https://doi.org/10.1016/j.ejso.2016.11.010>
3. Bartelink H, Horiot J, Poortmans P, Struikmans H, Van den Bogaert W, Barillot I, Fourquet A, Borger J, Jager J, Hoogenraad W, Collette L, Pierart M. Recurrence Rates after Treatment of Breast Cancer with Standard Radiotherapy with or without Additional Radiation. *New England Journal of Medicine*. 2001 Nov 08;345(19):1378-1387. <https://doi.org/10.1056/nejmoa010874>
4. Waljee JF, Hu ES, Ubel PA, Smith DM, Newman LA, Alderman AK. Effect of Esthetic Outcome After Breast-Conserving Surgery on Psychosocial Functioning and Quality of Life. *Journal of Clinical Oncology*. 2008 07 10;26(20):3331-3337. <https://doi.org/10.1200/jco.2007.13.1375>
5. Curran D, van Dongen J, Aaronson N, Kiebert G, Fentiman I, Mignolet F, Bartelink H. Quality of life of early-stage breast cancer patients treated with radical mastectomy or breast-conserving procedures: results of EORTC trial 10801. *European Journal of Cancer*. 1998 02;34(3):307-314. [https://doi.org/10.1016/s0959-8049\(97\)00312-2](https://doi.org/10.1016/s0959-8049(97)00312-2)
6. Foersterling E, Golatta M, Hennigs A, Schulz S, Rauch G, Schott S, Domschke C, Schuetz F, Sohn C, Heil J. Predictors of early poor aesthetic outcome after breast-conserving surgery in patients with breast cancer: Initial results of a prospective cohort study at a single institution. *Journal of Surgical Oncology*. 2014 08 08;110(7):801-806. <https://doi.org/10.1002/jso.23733>
7. Hennigs A, Hartmann B, Rauch G, Golatta M, Tabatabai P, Domschke C, Schott S, Schütz F, Sohn C, Heil J. Long-term objective esthetic outcome after breast-conserving therapy. *Breast Cancer Research and Treatment*. 2015 08 13;153(2):345-351. <https://doi.org/10.1007/s10549-015-3540-y>
8. Ojala K, Meretoja T, Leidenius M. Aesthetic and functional

- outcome after breast conserving surgery – Comparison between conventional and oncoplastic resection. *European Journal of Surgical Oncology (EJSO)*. 2017 04;43(4):658-664. <https://doi.org/10.1016/j.ejso.2016.11.019>
9. Peiris L, Olson D, Dabbs K. Oncoplastic and reconstructive breast surgery in Canada: breaking new ground in general surgical training. *Canadian Journal of Surgery*. 2018 Oct;;294-299. <https://doi.org/10.1503/cjs.016717>
 10. Spear S. *Surgery of the breast: Principles and Art*: Philadelphia, PA: Wlters Kluwer/Lippincott Williams & Wilkins, [Google scholar]. 2010.
 11. Anderson B, Masetti R, Silverstein M. Oncoplastic approaches to parial mastectomy : an overview of volume -displacement techniques. *Lancet oncol*. 2005;6:145-57.
 12. Kronowitz SJ, Hunt KK, Kuerer HM, Strom EA, Buchholz TA, Ensor JE, Koutz CA, Robb GL. Practical Guidelines for Repair of Partial Mastectomy Defects Using the Breast Reduction Technique in Patients Undergoing Breast Conservation Therapy. *Plastic and Reconstructive Surgery*. 2007 Dec;120(7):1755-1768. <https://doi.org/10.1097/01.prs.0000287130.77835.f6>
 13. Mansfield L, Agrawal A, Cutress R. Oncoplastic breast conserving surgery. *Gland Surg*. 2013;2(3):158-62. <https://doi.org/10.3978/j.issn.2227-684X.2013.08.04>
 14. Rocco N, Catanuto G, Cinquini M, Audretsch W, Benson J, Criscitiello C, Di Micco R, Kovacs T, Kuerer H, Lozza L, Montagna G, Moschetti I, Nafissi N, O'Connell RL, Oliveri S, Pau L, Scaperrotta G, Thoma A, Winters Z, Nava MB. Should oncoplastic breast conserving surgery be used for the treatment of early stage breast cancer? Using the GRADE approach for development of clinical recommendations. *The Breast*. 2021 06;57:25-35. <https://doi.org/10.1016/j.breast.2021.02.013>
 15. Youssef MMG, Namour A, Youssef OZ, Morsi A. Oncologic and Cosmetic Outcomes of Oncoplastic Breast Surgery in Locally Advanced Breast Cancer After Neoadjuvant Chemotherapy, Experience from a Developing Country. *Indian Journal of Surgical Oncology*. 2017 08 15;9(3):300-306. <https://doi.org/10.1007/s13193-017-0689-3>
 16. Clough KB, Lewis JS, Couturaud B, Fitoussi A, Nos C, Falcou M. Oncoplastic Techniques Allow Extensive Resections for Breast-Conserving Therapy of Breast Carcinomas. *Annals of Surgery*. 2003 01;237(1):26-34. <https://doi.org/10.1097/00000658-200301000-00005>
 17. Kurt Yazar S, Altinel D, Serin M, Aksoy S, Yazar M. Oncoplastic Breast Conserving Surgery: Aesthetic Satisfaction and Oncological Outcomes. *European Journal of Breast Health*. 2018 01 02;14(1):35-38. <https://doi.org/10.5152/ejbh.2017.3512>
 18. Bulstrode N, Shrotria S. Prediction of cosmetic outcome following conservative breast surgery using breast volume measurements. *The Breast*. 2001 04;10(2):124-126. <https://doi.org/10.1054/brst.2000.0197>
 19. Cochrane RA, Valasiadou P, Wilson ARM, Al-Ghazal SK, Macmillan RD. Cosmesis and satisfaction after breast-conserving surgery correlates with the percentage of breast volume excised. *British Journal of Surgery*. 2003 Nov 03;90(12):1505-1509. <https://doi.org/10.1002/bjs.4344>
 20. Houssami N, Macaskill P, Marinovich ML, Dixon JM, Irwig L, Brennan ME, Solin LJ. Meta-analysis of the impact of surgical margins on local recurrence in women with early-stage invasive breast cancer treated with breast-conserving therapy. *European Journal of Cancer*. 2010 Dec;46(18):3219-3232. <https://doi.org/10.1016/j.ejca.2010.07.043>
 21. Houssami N, Macaskill P, Luke Marinovich M, Morrow M. The Association of Surgical Margins and Local Recurrence in Women with Early-Stage Invasive Breast Cancer Treated with Breast-Conserving Therapy: A Meta-Analysis. *Annals of Surgical Oncology*. 2014 01 29;21(3):717-730. <https://doi.org/10.1245/s10434-014-3480-5>
 22. Shah C, Verma V, Sayles H, Recht A, Vicini F. Appropriate margins for breast conserving surgery in patients with early stage breast cancer : a meta - analysis. In: *Proceedings of the 2017 San Antonio Breast Cancer Symposium, San Antonio, TX, 5 - 9 December Cancer Res 2018; 78 (suppl): Abstract nr Gs5 - 01*. 2017.
 23. André C, Holsti C, Svenner A, Sackey H, Oikonomou I, Appelgren M, Johansson ALV, de Boniface J. Recurrence and survival after standard versus oncoplastic breast-conserving surgery for breast cancer. *BJS Open*. 2021 01;5(1). <https://doi.org/10.1093/bjsopen/zraa013>
 24. Rose M, Manjer J, Ringberg A, Svensson H. Surgical strategy, methods of reconstruction, surgical margins and postoperative complications in oncoplastic breast surgery. *European Journal of Plastic Surgery*. 2014 02 01;37(4):205-214. <https://doi.org/10.1007/s00238-013-0922-4>
 25. Santos G, Urban C, Edelweiss MI, Zucca-Matthes G, de Oliveira VM, Arana GH, Iera M, Rietjens M, de Lima RS, Spautz C, Kuroda F, Anselmi K, Capp E. Long-Term Comparison of Aesthetical Outcomes After Oncoplastic Surgery and Lumpectomy in Breast Cancer Patients. *Annals of Surgical Oncology*. 2014 Dec 18;22(8):2500-2508. <https://doi.org/10.1245/s10434-014-4301-6>
 26. Bertozzi N, Pesce M, Santi P, Raposio E. oncoplastic breast surgery: comprehensive review. *Eur Rev Med Phar S*. 2017;21:2572-85.
 27. Dahlbäck C, Manjer J, Rehn M, Ringberg A. Determinants for patient satisfaction regarding aesthetic outcome and skin sensitivity after breast-conserving surgery. *World Journal of Surgical Oncology*. 2016 Dec;14(1). <https://doi.org/10.1186/s12957-016-1053-8>
 28. Fitoussi AD, Berry MG, Famà F, Falcou M, Curnier A, Couturaud B, Reyat F, Salmon RJ. Oncoplastic Breast Surgery for Cancer: Analysis of 540 Consecutive Cases. *Plastic and Reconstructive Surgery*. 2010 02;125(2):454-462. <https://doi.org/10.1097/prs.0b013e3181c82d3e>
 29. Kosasih S, Tayeh S, Mokbel K, Kasem A. Is oncoplastic breast conserving surgery oncologically safe? A meta-analysis of 18,103 patients. *The American Journal of Surgery*. 2020 08;220(2):385-392. <https://doi.org/10.1016/j.amjsurg.2019.12.019>



This work is licensed under a Creative Commons Attribution-Non Commercial 4.0 International License.