

# Frozen Section Versus Permanent Section in Cancer Diagnosis: A Single Centre Study

Barasha Sarma Bharadwaj, Muktanjalee Deka, Manisha Salvi, B K Das, B C Goswami

Department of Oncopathology, State Cancer Institute, Guwahati, Assam, India.

## Abstract

**Introduction:** Frozen section is an intraoperative pathological technique which has very important role to play in diagnostics and also it plays important role in further surgical management as specially in oncology setup. Most common indications for frozen section were confirmation of neoplasms, evaluation of margins status, evaluation of metastasis etc. **Materials and Methods:** This is a prospective study of 200 frozen section cases, where frozen sections were compared with permanent Haematoxylin and Eosin stained slides. Accuracy of frozen sections were analysed with various parameters like true positive, false positive, sensitivity, specificity, concordance rate etc. **Results:** Highest number cases were from gall bladder/ biliary tract (45) followed by breast tissue (43), lymph node (32) etc. Diagnostic accuracy of frozen section was 95.5% (191/200 cases) when compared with permanent section. Concordance rate was 191 (95.5%), sensitivity 89.5% with positive predictive value 96.7% and negative predictive value 94.9% respectively. **Conclusion:** Adequate and accurate sampling is recommended and also interpretation error should be minimized to help reducing the rate of discordant cases.

**Keywords:** frozen section- permanent section- oncological surgery

*Asian Pac J Cancer Care*, 7 (2), 247-251

Submission Date: 02/05/2022    Acceptance Date: 04/12/2022

## Introduction

The frozen section is a pathological technique of microscopic analysis of tissue in order to make a rapid diagnosis, most often performed in oncological surgery. Frozen section was first performed by Welch in 1891 for intra-operative consultation and further development was contributed by Cullen in 1895 and Wilson in 1905. Then in 1920s this technique became popular and was used for intraoperative consultation in everyday practice. Teloh HA made the final development by placing the unfixed specimen onto the freezing stage of the microtome in 1957. Intermittent release of carbon dioxide gas was done to cause rapid freezing of the tissue. Cryostat was developed in 1959, which is basically a cryomicrotome has revolutionized the frozen section technique. The cryostat is a refrigerated box containing a rotary microtome with inside temperature of the cryostat is about  $-20^{\circ}$  to  $-30^{\circ}$  Celsius. Frozen section provides rapid gross and microscopic diagnosis in guiding intra or perioperative

management of a patient, including nature and type of lesion whether it is benign or malignant, status of surgical margins, identification of lymph node status or simply representation of biopsy specimen. Besides breast, specimens from head & neck surgery and neurosurgery are some of the most commonly received specimens in frozen section [1,2].

However, frozen section has its own limitations like frozen section artifacts, poor quality of sections, suboptimal histology, poor quality staining, pressure of immediate diagnosis and lack of ancillary studies at the time of intraoperative consultation. Therefore frozen sections should not be considered as replacement of the permanent sections. Case discussion is important before frozen section, case details including relevant clinical and radiological information should be provided to the reporting pathologist. The surgeon and the pathologist should act like a team to achieve a meaningful frozen report. Some well differentiated tumors or tumors which

## Corresponding Author:

Dr. Barasha Sarma Bharadwaj  
Department of Oncopathology, State Cancer Institute, Guwahati, Assam, India.  
Email: sarmabarasha@rediffmail.com

present with heterogeneity or tumors with extensive necrosis are really difficult to interpret in frozen section. Even capsular invasion interpretation in case thyroid follicular neoplasm is a challenging task in a limited time frame. Similarly diagnostic accuracy of malignant melanoma or melanocytic lesion is contraindicated in frozen section [1-3].

Accuracy of the frozen section reports helps in further proper clinical management and it has emerged as an essential tool. Therefore evaluation of the performance standard of the frozen section reports is essential for a tertiary care centre for better therapeutic approach.

This is a single institution study, with an aim to analyze the accuracy of frozen section vs permanent paraffin section. Inclusion criteria for the study was all in house surgical procedures who underwent intraoperative frozen sections.

## Materials and Methods

It is a prospective study for a time period of two years, from September 2019 to October 2021 in a tertiary cancer care centre. Total 200 cases of frozen sections were evaluated for the study.

The gross specimens were received from the operation theatre in the fresh state, grossing is done immediately. Various measurements were taken, any suspected tumor or abnormal area if identified, sections are taken after proper measurement and description of the lesion. In case of the lesions where margin status was requested for example, wide local excision specimen, lumpectomy etc exact distance of the lesion from the cut margin was measured and representative sections were submitted. Sections were kept in mounting medium and kept for freezing in -25 to -30 degree centigrade in the chamber of cryostat. 6-7 micron thick sections were taken on glass slides and stained with rapid haematoxylin and eosin stain and examined under microscope. Results were informed immediately to surgeon.

For routine formalin fixed paraffin embedding (FFPE) tissue processing: The specimens were received in 10% buffered formalin, after routine grossing, tissue processing and staining with haematoxylin and eosin slides were evaluated for final histopathology and compared with the frozen results.

The tissue received for frozen section were primarily from hepatobiliary system, followed by lumpectomy specimen of breast, lymph nodes, penectomy, soft tissue, ovary etc.

Most common indications for frozen section were as follows:

- 1) Presence, verification and categorization of neoplasms in 83 (41.5%),
- 2) Evaluation of margins in 98 (49%)
- 3) Evaluation of metastasis 44 (22%)

### Statistical analysis

Comparison of frozen sections will be done with the permanent sections to see the accuracy. Sensitivity, specificity, PPV (positive predictive value) and NPV

(negative predictive value) are calculated to compare the results.

## Results

Results were analyzed based on evaluation of both frozen reports and final histopathology report. Specimens received from gall bladder/ biliary tract were highest in number (45), followed by breast tissue (43), lymph node (32), soft tissue (21), penectomy (20), ovarian tissue (19), gastrointestinal tract (15), omental tissue (7), liver (5), larynx (2) and thyroid (1). (Figure1- 5).

Number of tissues evaluated were 550 in 200 cases. Table 1.

Diagnostic accuracy of frozen section was 95.5% (191/200 cases) when compared with permanent section. Discordance was found in nine cases with false negative diagnoses in 7 cases and false positive diagnosis in 2 cases. Out of total 200 cases concordance and discordance rates between frozen section and permanent section were 191 (95.5%) and 9 (4.5%) respectively, sensitivity 89.5%, specificity 98.5%, positive predictive value 96.7% and negative predictive value was 94.9%. Table 2, Table 3.

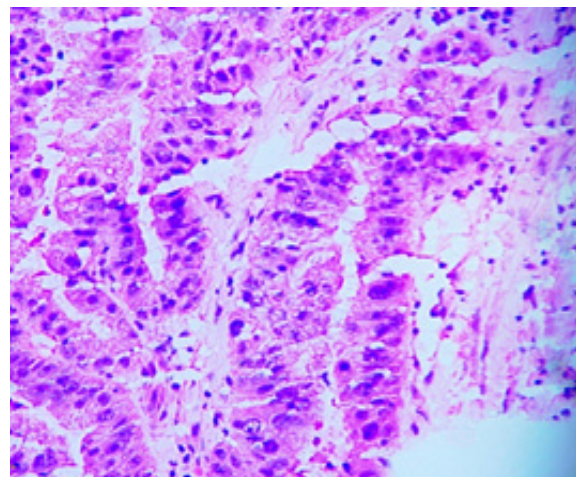


Figure 1. Gall Bladder Adenocarcinoma

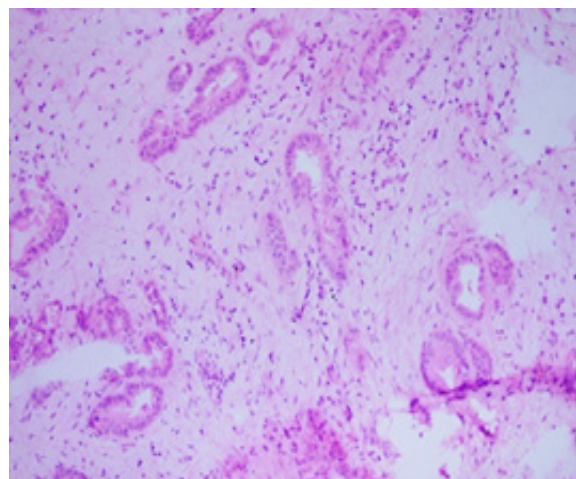


Figure 2. Gall Bladder Adenocarcinoma

Table 1. Tissue Types with Concordance and Discordance

Serial no.	Tissue type	No. of cases	No. of tissues	Concordant cases	Discordant cases
1	Gall bladder/ biliary tract	45	77	40	5
2	Breast tissue	43	207	43	0
4	Lymph node	32	112	32	0
5	Soft tissue	21	36	21	0
6	Penectomy	20	31	20	0
7	Ovarian tissue	19	44	16	3
8	GIT	15	20	14	1
9	Liver	7	7	7	0
10	Omental tissue	5	7	5	0
11	Larynx	2	5	2	0
12	Thyroid	1	3	1	0
	Total	200	550	191	9

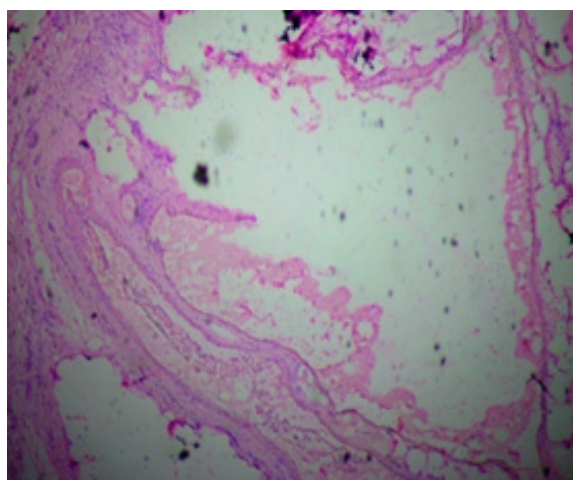


Figure 3. Pseudomyxoma Peritonei

## Discussion

Frozen section is a multistep intraoperative diagnostic procedure which plays a major role in management of especially in various neoplastic diseases. It is useful in determining the extent of surgery. Such as presence or absence of neoplasms is important, as this will decide the type of operative procedure or further management. Also, margin status of a malignant lesion is crucial as tumor recurrence can be avoided by achieving adequate margin as specially in head and neck malignancies, lumpectomy specimens or resected margin status can be of utmost importance especially in cystic duct cut margin in gall bladder tumor, ureteric cut margin in bladder resection

Table 2. True Positive, False Positive, True Negative and False Negative Cases

True positive – 60	False positive – 2
False negative – 7	True negative – 131

Table 3. Sensitivity, Specificity, Positive Predictive Value, Negative Predictive Value and Accuracy

Sensitivity (%)	Specificity (%)	Positive predictive value (%)	Negative predictive value (%)	Accuracy (%)
89.5	98.5	96.7	94.9	95.5

specimen or urethral cut margin in penectomy etc. By comparing frozen section with permanent sections we also tried to evaluate the diagnostic accuracy of frozen section in the institution.

Total number of concordant was 191 (95.5%) which was similar to study done by Hatami H et al, (97.96%). [6]. Discordance was 9 (4.5%) which was comparable to other studies by Brunner A et al, Mahe E et al and Hatami H et al. [4-6] Table 4.

Diagnostic accuracy of frozen section was 95.5% (191/200 cases) in our study which is comparable to other studies like Preeti A et al (94.2%) [7].

Among the 9 discordant cases false negative diagnoses was in 7 cases and false positive diagnosis in 2 cases. There was 3 false positive and 2 false negative cases in study conducted by Khoo JJ et al. [8].

In our study sensitivity was 89.5%, specificity 98.5%, positive predictive value 96.7% and negative predictive value was 94.9% which was comparable to study done by Brunner et al in 59 frozen section cases with sensitivity of 95%, and PPV 100%, specificity was 100%, and the negative predictive value was 90% and results were compatible to other studies also (Table 5).

Among the discordance cases, four cases were of specimen of gall bladder, in frozen section no evidence of malignancy was found in all four cases, however in permanent sections it was found to be cases of adenocarcinoma in three cases, the fourth case was intracholecystic papillary neoplasm with invasive foci. Out of the four cases two cases were due interpretation error, rest two cases of discordance was due to sampling error. One case was of cystic duct cut margin which was reported negative in frozen section, in permanent sections it was reported as mild dysplasia. Another series of discordance was observed in three cases of ovarian tumor, mostly due to sampling error, which was reported as benign / borderline tumor in frozen, however in permanent sections two cases were of serous carcinoma

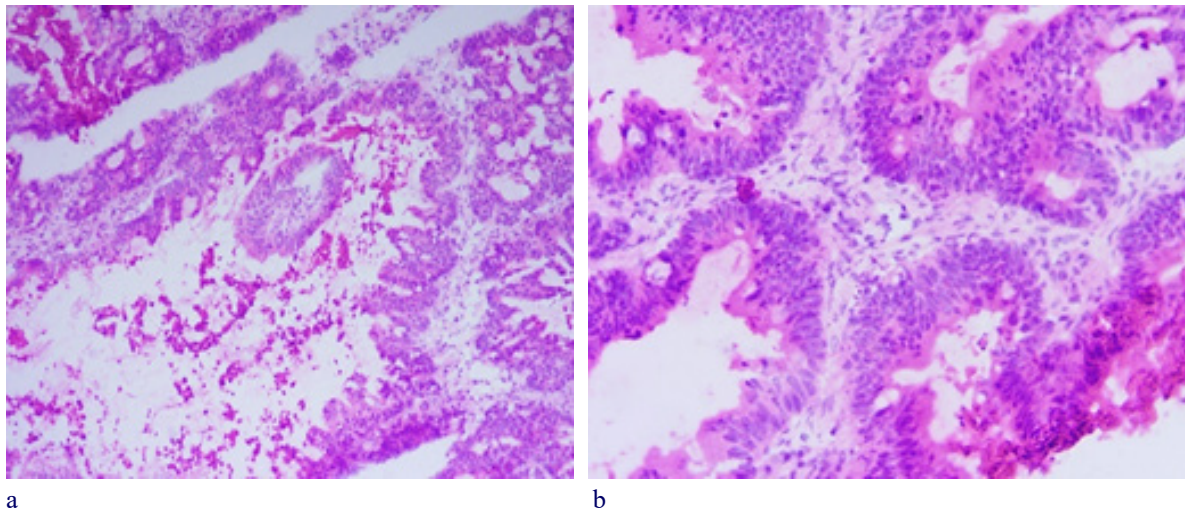


Figure 4. a and b, Ovary Serous Cystadenocarcinoma

Table 4. Comparison of Discordance with Various other Studies

	Brunner A.H et al [4]	Mahe E et al [5]	Hatami H et al [6]	Present study
No of cases	59	812	295	200
Discordance rate	3.3	2%	2.03%	4.5

Table 5. Comparison of Sensitivity, Specificity, Positive Predictive Value and Negative Predictive Value with Various other Studies

	Brunner A.H et al [4]	Preeti A et al [7]	Hatami H et al [6]	Present study
No of cases	59	224	295	200
Sensitivity (%)	95	75	92.95	89.50
Specificity (%)	100	97.54	99.55	98.50
Positive predictive value (%)	100	90.90	98.50	96.70
Negative predictive value (%)	90	94	97.80	94.9

Table 6. Discordant Cases between Frozen and Permanent Section

Types of tissue	Diagnosis in frozen section	Diagnosis in permanent section	Causes for discordance	Number of cases
Gall bladder	Benign	Malignant	Interpretation error	1
Gall bladder	Benign	Intracholecystic papillary neoplasm with invasive foci	Interpretation error	1
Gall bladder	Benign	Malignant	Sampling error	2
Cystic duct cut margin	Negative	Mild dysplasia	Interpretation error	1
Ovary	Benign	Metastatic adenocarcinoma to ovary	Sampling error	1
Ovary	Borderline	Malignant	Sampling error	1
Ovary	Borderline	Malignant	Interpretation error	1
Colon	Poorly differentiated adenocarcinoma	Non hodgkin lymphoma	Interpretation error	1

and one was reported as metastatic adenocarcinoma in ovary. Ninth case was of colon which came out as a case of lymphoma in permanent sections, it was reported as poorly differentiated adenocarcinoma in frozen section which was due to interpretation error (Table 6).

Experience plays a major role in interpretation of frozen sections slides, also evaluation of the specimens by two observers or even three, when there is uncertainty

may help in reducing the rate of error.

In conclusion, we can conclude that frozen section is a highly accurate and reliable test with practically no false positive results in our study and it can be used as a highly effective intraoperative procedures which can help in further surgical management. In our study, frozen section discrepancy was due to both sampling error and misinterpretation error. Interpretation error was

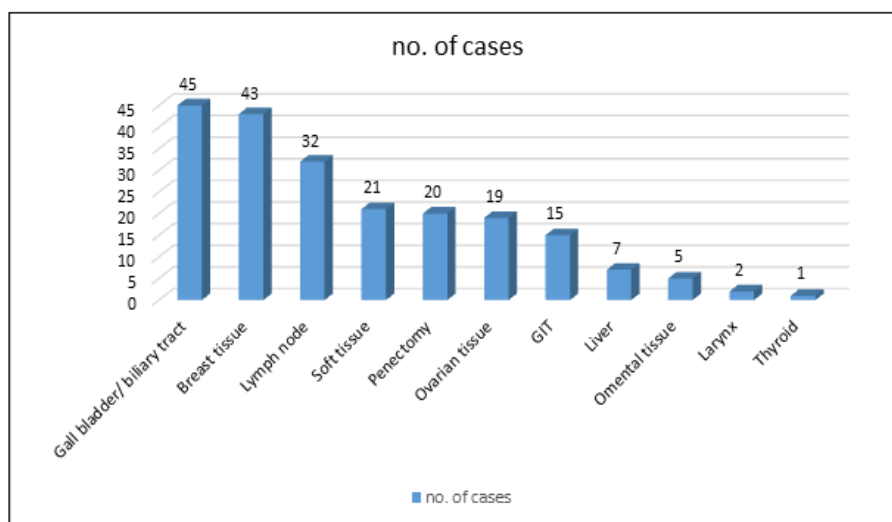


Figure 5. Distribution of Specimen According to Anatomical Sites/tissue Types

due to various technical limitation of frozen section like freezing artifact, compression artifact due to expanding ice bubbles in edematous tissue, obscured nuclear details due nuclear ice crystals, nuclear chromatin changes, shrinkage artifacts followed by sectioning etc. Sampling error should be minimal and also proper communication between pathologist and surgeon is very important to help reducing the rate of discordant.

#### Conflict of interest

There is no conflict of interest among authors.

#### References

1. Rs S. Reliability of frozen sections in the diagnosis of breast lesions. *Annals of surgery*. 1962 06;155(6). <https://doi.org/10.1097/0000658-196206000-00012>
2. Jaafar H. Intra-operative frozen section consultation: concepts, applications and limitations. *Malays J Med Sci*. 2006 Jan;13(1):4-12.
3. H J, W M, H T. Accuracy of frozen section diagnosis in nodular goiter. *Annals of surgery*. 1962 02;155(2). <https://doi.org/10.1097/0000658-196200000-00022>
4. Ah B, T S, J K, P R, H B. The accuracy of frozen section analysis in ultrasound- guided core needle biopsy of breast lesions. *BMC cancer*. 2009 09 24;9. <https://doi.org/10.1186/1471-2407-9-341>
5. Mahe E, Ara S, Bishara M, Kurian A, Tauqir S, Ursani N, Vasudev P, Aziz T, Ross C, Lytwyn A. Intraoperative pathology consultation: error, cause and impact. *Canadian Journal of Surgery. Journal Canadien De Chirurgie*. 2013 06;56(3):E13-18. <https://doi.org/10.1503/cjs.011112>
6. Hatami H, Mohsenifar Z, Alavi S. The Diagnostic Accuracy of Frozen Section Compared to Permanent Section: A Single Center Study in Iran. *Iran J Pathol*. 2015;10(4):295-9.
7. Preeti A, Sameer G, Kulranjan S, Arun Abhinav S, Preeti R, Sunita Y, Madhu Mati G. Intra-Operative Frozen Sections: Experience at A Tertiary Care Centre. *Asian Pacific journal of cancer prevention: APJCP*. 2016 Dec 01;17(12):5057-5061. <https://doi.org/10.22034/APJCP.2016.17.12.5057>
8. Khoo J. An audit of intraoperative frozen section in Johor. *Med J Malaysia*. 2004 Mar;59(1):50-5. PMID :15535336



This work is licensed under a Creative Commons Attribution-Non Commercial 4.0 International License.