

# Clinicopathological Spectrum of Thyroid Swelling: A Single Institutional Prospective Study from Northeast India

Michimi Daimary

R N Choubey

Jyotiman Nath

Pathology (FAAMCH-Barpeta, Assam), India.

Silchar Medical College, Silchar, India.

Dr B Borooah Cancer Institute, Guwahati, India.

**Purpose:** The pathologic lesions of the thyroid gland are manifested by varied morphologies. The current study aims to report the clinicopathologic features of patients with thyroid swelling from a tertiary centre of North-East India with particular emphasis on histopathological examination (HPE).

**Method:** It is a prospective hospital-based study. Fifty-three resected specimens of thyroid surgery were included in the study. All the specimens were undertaken for HPE, and the malignant cases were subjected to immunohistochemistry (IHC).

**Results:** Female preponderance (84.9%) of the disease was found with a maximum incidence between the age group younger than 40 (60.37%). 86.8% of cases were benign on HPE; colloid goitre reported a maximum number (62.3%). Only seven cases were found malignant, and six out of them were papillary carcinoma. All the six papillary carcinomas and one follicular carcinoma showed immunoreactivity of tumour cells to TTF 1, CK 7 and Thyroglobulin.

**Conclusion:** Asymptomatic thyroid swelling is a prevalent entity, and the incidence of malignancy in the current study is 13.2%. Identifying malignant thyroid swelling out of the common benign or apparently benign goitres has always been problematic, and preoperative fine-needle aspiration cytology followed by HPE and IHC plays a significant role.

## Introduction

Thyroid lesions are common among the general population. Diseases of the thyroid include conditions associated with excessive release of thyroid hormones (hyperthyroidism), those associated with thyroid hormone deficiency (hypothyroidism), and neoplasms of the thyroid [1].

The pathologic lesions of the thyroid gland are manifested by varied morphologies. Despite many lesions, it is convenient to consider them as divided into two major types: those that show a diffuse pattern and those that produce nodules. Diffuse thyroid lesions are associated with conditions affecting the entire gland, such as hyperplasia and thyroiditis. The term thyroid nodule is referred to a clinically or radiologically discernable lesion within the thyroid gland [2]. Thyroid nodules are detected clinically in 4-7% in the general population and found incidentally on ultrasonography in 19 – 67 %. The majority of thyroid nodules are asymptomatic, but 5% of all palpable thyroid nodules are malignant [3]. Although thyroid function tests, scintigraphy, and ultrasound were routinely used to diagnose thyroid nodules, they could not discriminate between benign and malignant lesions [4].

The frozen section has served well in the past in intraoperative diagnosis of thyroid cancer and determination of the extent of thyroidectomy. However, the emergence of increasingly accurate and cheap methods of pre-and intraoperative fine needle aspiration biopsy (FNAB) has raised questions about the routine use of frozen sections as an intraoperative diagnostic tool [5-7]. Moreover, the refinement in imaging, combined with the preoperative availability of fine-needle aspiration cytology (FNAC), has enhanced the ability of surgeons to plan procedures more appropriately. Knowledge in the field of thyroid pathology has been snowballing in recent years.

Immunohistochemically, many markers have been documented in normal thyroid follicular cells, most expressed in well-differentiated tumours. These markers have been evaluated in normal tissues, benign and malignant tumours, hoping to find significantly different values among these groups that could be explored diagnostically [8].

The current study was undertaken to assess the clinicopathologic features of patients with thyroid swelling from a tertiary centre of North-East India.

## Materials and Methods

This prospective study was conducted in the department of Pathology in a tertiary health care centre of northeast India for one year. Total 53 thyroid resected specimens clinically presenting with thyroid swelling were included in the study. Preoperative FNAC followed by post-operative histopathology examination (HPE) and immunohistochemistry (IHC) for malignant tumours with TTF-1, Thyroglobulin and CK-7 were done per IHC protocol in the malignant thyroid cases.

### Histopathological examination

Thyroid specimens received were fixed in 10% formalin, and detailed gross examination was done and recorded accordingly. The samples were then sectioned from representative areas, and tissue sections were by Hematoxylin and Eosin.

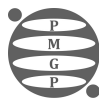
### Immunohistochemistry

After section cutting, the selected paraffin embedded tissue blocks of malignant thyroid tumours were taken up on poly-lysine coated slides for the IHC procedure. The following primary antibodies were used: antibody to cytokeratin 7 (OV-TL 12/30, mouse monoclonal, prediluted, CELL MARQUE), antibody to thyroglobulin (MRQ-41, mouse monoclonal, prediluted, CELL MARQUE), and antibody to thyroid transcription factor-1 (8G7G3/1, mouse monoclonal, prediluted, CELL MARQUE). The positive controls used were sections of adenocarcinoma of the lung for CK7 and TTF-1 and sections of normal thyroid for thyroglobulin. The negative controls used were sections of the study tissues with no primary antibody incubation. All immunohistochemical scoring of immunostained slides was conducted according to the percentage of tumour cells exhibiting cytoplasmic staining for Thyroglobulin and CK7 and nuclear staining for TTF-1. [9] The results were scored as 0 staining in less than 5% of tumour cells 1+ staining in 5% - 30% of tumor cells 2+ staining in more than 30% of tumour cells Baseline variables were depicted as number (percentage), mean  $\pm$  SD and median. Statistical analysis was conducted with Microsoft Office Excel V. 2007.

## Results

The baseline patient characteristics are depicted in Table 1.

Characteristics	Number	Percentage
Age		
<40	32	60.37
40-60	17	32.07
>60	4	7.54
Median	38 Years	Range 25-69
Sex		
Male	8	15.1
Female	45	84.9
Clinical		



Cystic	11	20.75
Solid	29	54.72
Mixed	13	24.53
USG		
Cystic	4	7.55
Solid	43	81.13
Mixed	6	11.32
Baseline TSH		
Hypothyroid	3	5.66
Euthyroid	48	90.56
Hyperthyroid	2	3.77
History		
Swelling Only	28	52.83
Swelling with Pain	11	20.75
Swelling with Fever	1	1.88
Swelling with Dysphagia	13	24.52
Location		
Right lobe	25	47.16
Left Lobe	26	49.05
Bilateral	2	3.77

**Table 1. Baseline Patient Characteristics (n=53).**

Among the study cohort, the majority were female patients (45 patients, 84.90%). The median age of presentation was 38 years (range 25-69 years). Clinically 29 patients (54.72%) had solid consistency of the swelling, 11 patients (20.75%) had cystic swelling and the remaining 13 patients (24.53%) had mixed consistency. When it was confirmed by ultrasonography, 43 patients (81.13%) had solid consistency, four patients (7.55%) had cystic swelling, and the remaining six patients (11.32%) had mixed consistency. The majority of the patients (48 patients, 90.56%) were euthyroid at presentation. Only three patients (5.66%) were hypothyroid, and two (3.77%) were hyperthyroid.

Table 2 shows the FNAC interpretation of the thyroid swellings during the evaluation. In 43% of cases, it was reported as benign and only in 3 cases (5.66%) the malignancy was reported. Ten patients (18.86%) had unsatisfactory aspiration, and nine patients (16.98%) had the indeterminate neoplasia interpretation.

FNAC Interpretation	Number	Percentage
Benign	23	43.39
Malignant	3	5.66
Suspicious of Neoplasia	8	15.09
Unsatisfactory aspiration	10	18.86
Indeterminate of neoplasia	9	16.98

**Table 2. FNAC Interpretation of Thyroid Nodules.**

Table 3 depicts the histopathological diagnosis of the 53 patients operated on for thyroid swellings. The majority of the cases (46 patients, 86.8%) were benign, the commonest being the colloid goitre (62.3%), followed by follicular adenoma (11.3%). Malignancy was found in seven cases (13.2%). Papillary carcinoma was the commonest malignancy accounting for 6 cases (11.3%). One case of Follicular carcinoma was diagnosed.

Histopathological Diagnosis		Number of patients	Percentage (%)
Benign	Colloid goiter	33	62.30
	Nodular hyperplasia	2	3.80

	Hashimoto's thyroiditis	4	7.50
	Follicular adenoma	6	11.30
	Hurthle cell adenoma	1	1.90
	Total	46	86.80
Malignant	Papillary carcinoma	6	11.30
	Follicular carcinoma	1	1.90
Total		7	13.20
Grand Total		53	100

**Table 3. Histopathological Diagnosis of Thyroid Swellings.**

IHC with TTF-1, Thyroglobulin and CK-7 was done as per IHC protocol in the malignant thyroid cases. Table 4 depicts the IHC findings of the malignant cases.

Sl no.	Age	Sex	Histological type	TTF 1	CK 7	TG
1	16	M	Papillary thyroid carcinoma	2+	2+	2+
2	33	F	Papillary thyroid carcinoma	2+	2+	2+
3	38	F	Papillary thyroid carcinoma	2+	2+	2+
4	48	M	Papillary thyroid carcinoma	2+	2+	2+
5	49	M	Papillary thyroid carcinoma	1+	2+	2+
6	67	M	Papillary thyroid carcinoma	2+	2+	1+
7	56	F	Follicular carcinoma	2+	1+	1+

**Table 4. IHC Expression of TTF 1, CK 7 and Thyroglobulin in Malignant Thyroid Cases.**

All the six papillary carcinomas and one follicular carcinoma showed immunoreactivity of tumour cells to TTF 1, CK 7 and Thyroglobulin. Positive control for TTF 1 showed strong nuclear staining. Positive control for CK 7 and Thyroglobulin showed strong cytoplasmic staining. Table 5 shows the staining pattern of TTF 1, CK 7 and Thyroglobulin in Papillary thyroid carcinomas.

		TTF 1			CK 7			Thyroglobulin	
IHC Score	0	1+	2+	0	1+	2+	0	1+	2+
No.	0	1	5	0	0	6	0	1	5
Percentage (%)	0	16.70	83.30	0	0	100	0	16.70	83.3

**Table 5. Staining Pattern of TTF 1, CK 7 and Thyroglobulin in Papillary Thyroid Carcinomas.**

Papillary carcinomas showed strong diffuse nuclear positivity to TTF 1 in 83.3% (5/6) cases, weak focal nuclear positivity to TTF 1 in 16.7% (1/6), strong diffuse cytoplasmic positivity to CK 7 in 100 % (6/6) cases, strong diffuse cytoplasmic positivity to Thyroglobulin in 83.3% (5/6) cases, weak focal cytoplasmic positivity to Thyroglobulin in 16.7% (1/6). Follicular carcinoma showed strong diffuse nuclear positivity to TTF 1, weak focal cytoplasmic positivity to CK 7 and weak focal cytoplasmic positivity to Thyroglobulin.

## Discussion

The present study attempts to report the clinicopathologic features of patients with thyroid swelling from a tertiary centre of North-East India. A total of 53 patients were included in the study, and the majority were female patients (84.90%). There is significant female preponderance in similar studies by Russel Kahmke et al., and Bahadir Cetin et al. showed 77.4% and 77.3% females, respectively [10,11]. The majority of the patients (60.37%) in the current study were below 40. The age distribution is similar to many other published pieces of literatures. In a clinicopathological study of incidentally revealed thyroid swellings in Bihar, India, the highest incidence of thyroid swelling (75.84%) was found in the age group of 20-40 years; a female preponderance was noted in the ratio 4:1 [12].

Ninety per cent of the cases in the present had euthyroid status. Hypothyroidism and hyperthyroidism were observed in 5.66 % and 3.7% of the cases, respectively. Similar results are reported by other published literature [13,14].

In the current study, the distribution of thyroid nodules is approximately similar in both lobes. The site of thyroid nodule in gland varied in reports of different study groups; most have found the right lobe to be affected more [15-17].

The swelling was the only symptom in most patients in our study (28 patients, 52.83%). Eleven patients (20.75%) gave a history of swelling with pain, and 13 patients (24.52) had a history of swelling with varied grades of dysphagia. In his series of 600 cases, Bhansali SK also reported that pain and dysphagia were reported by 13% and 12% patients respectively; but the majority of the cases were without any symptom [18]. In the study by Pal R et al., 93.2% of cases presented with neck swelling only [12].

On HPE, 46 patients (86.8%) had benign, and seven patients (13.2%) had malignant pathology. Colloid goitre was the most common benign pathology reported (33 patients, 62.3%). A study of 203 patients with nodular thyroid disease reported 76.4% patients with benign and 23.6% with malignant pathology [11].

The colloid goitre is the commonest among the benign thyroid nodules [19] In the current study also, the colloid goitre was commonest, followed by the follicular adenoma. This is similar to the study by Tamimi DM, who found colloid goitre (51%) to be the most common benign lesion followed by follicular adenoma (13%) [20]. In our study, six cases (11.3%) were papillary carcinoma out of seven malignant cases, and only one was follicular carcinoma (1.9%). This result correlates with the fact the papillary carcinoma is the most common variety of thyroid malignancies [21].

Immunohistochemistry with TTF-1, Thyroglobulin and CK-7 was done per IHC protocol in the seven malignant thyroid cases. All the six papillary carcinomas and one follicular carcinoma showed immunoreactivity of tumour cells to TTF 1, CK 7 and Thyroglobulin. Papillary carcinomas showed strong diffuse nuclear positivity to TTF 1 in 83.3% (5/6) cases, weak focal nuclear positivity to TTF 1 in 16.7% (1/6), strong diffuse cytoplasmic positivity to CK 7 in 100 % (6/6) cases, strong diffuse cytoplasmic positivity to Thyroglobulin in 83.3% (5/6) cases, weak focal cytoplasmic positivity to Thyroglobulin in 16.7% (1/6). Follicular carcinoma showed strong diffuse nuclear positivity to TTF 1, weak focal cytoplasmic positivity to CK 7 and weak focal cytoplasmic positivity to Thyroglobulin.

Fenton CL et al., in his study, showed that TTF-1 protein expression is detected in the nucleus of the majority of benign thyroid diseases and well-differentiated thyroid carcinomas [22]. Ordonez NG, in his study, showed that TTF-1 is positive in 96% of papillary, 100% of follicular, 20% of oxyphilic, and 90% of medullary carcinomas anaplastic carcinomas are essentially immunonegative for TTF-1 [23].

There is sufficient evidence of literature that showed that papillary carcinomas express strong and diffuse immunoreactivity for CK 7 in 80-100% of cases. The expression of CK7 is less frequent in cases of poorly differentiated carcinomas (60%). Medullary carcinomas have been reported to

express strong positive staining for CK7 and CK18 in 77% of cases [24,25].

In conclusion, the current study had reported various clinicopathologic features of thyroid swellings with histopathological diagnosis. The majority of thyroid swellings were benign, and colloid goitre was the commonest. Our study has confirmed that the expression of TTF-1, CK7 and Thyroglobulin is a valuable panel of immunohistochemical markers for diagnosis of papillary carcinoma and follicular carcinoma. However, there are many limitations in the current study. Firstly, the sample size is very small, and secondly, the number of malignant cases was less. We did not get cases of poorly differentiated carcinoma, anaplastic carcinoma and medullary carcinoma. The clinical utility of TTF-1, CK7 and Thyroglobulin in thyroid cancer patients, has to be further defined by prospective studies with a larger sample size.

#### *Compliance with Ethical Standards*

##### *Ethical approval*

The study was approved by Institutional Ethics Committee of Silchar Medical College. Written informed consent was taken from all the patients.

##### *Conflicts of Interest*

The authors declare that they have no known competing financial interests or personal relationships that could have appeared to influence the work reported in this paper.

##### *Funding*

None.

This research did not receive any specific grant from funding agencies in the public, commercial, or not-for-profit sectors.

## References

## References

1. Robbins S, Kumar V, Cotran R. Robbins and Cotran pathologic basis of disease. 8th ed. Philadelphia, PA: Saunders/Elsevier; 2010.
2. Cooper DS, Doherty GM, Haugen BR, Kloos RT, Lee SL, Mandel SJ, Mazzaferri EL, et al. Revised American Thyroid Association management guidelines for patients with thyroid nodules and differentiated thyroid cancer. *Thyroid: Official Journal of the American Thyroid Association*. 2009; 19(11)[DOI](#)
3. Welker MY, Orlov D. Thyroid nodules. *American Family Physician*. 2003; 67(3)
4. Taneri F, Poyraz A, Salman B, Tekin E, Akyurek N, Bayram O, Onuk E. Using imprint and frozen sections in determining the surgical strategies for thyroid pathologies. *Endocrine Regulations*. 2001; 35(2)
5. Hamburger JI, Hamburger SW. Declining role of frozen section in surgical planning for thyroid nodules. *Surgery*. 1985; 98(2)
6. Keller MP, Crabbe MM, Norwood SH. Accuracy and significance of fine-needle aspiration and frozen section in determining the extent of thyroid resection. *Surgery*. 1987; 101(5)

7. DeMay RM. Frozen section of thyroid? Just say no. *American Journal of Clinical Pathology*. 1998; 110(4)[DOI](#)
8. ROSAI J. Rosai and ackerman's surgical pathology, 10e. 10th ed. India: ELSEVIER INDIA; 2011.
9. Choi YL, Kim MK, Suh JW, Han J, Kim JH, Yang JH, Nam SJ. Immunoexpression of HBME-1, high molecular weight cytokeratin, cytokeratin 19, thyroid transcription factor-1, and E-cadherin in thyroid carcinomas. *Journal of Korean Medical Science*. 2005; 20(5)[DOI](#)
10. Kahmke R, Lee WT, Puscas L, Scher RL, Shealy MJ, Burch WM, Esclamado RM. Utility of Intraoperative Frozen Sections during Thyroid Surgery. *International Journal of Otolaryngology*. 2013; 2013[DOI](#)
11. Cetin B, Aslan S, Hatiboglu C, Babacan B, Onder A, Celik A, Cetin A. Frozen section in thyroid surgery: is it a necessity?. *Canadian Journal of Surgery. Journal Canadien De Chirurgie*. 2004; 47(1)
12. Sengupta A, Pal R, Kar S, Zaman FA, Basu M, Pal S. Clinico-pathological correlates of incidentally revealed thyroid swelling in Bihar, India. *Journal of Pharmacy & Bioallied Sciences*. 2012; 4(1)[DOI](#)
13. Russel CFJ. The management of the solitary thyroid nodule. In: Johnson CD, Taylor I, editors. Recent advances in surgery. Vol. 17. London: ChurchillLivingstone; 1994; 4-16.
14. Kaplan EL, Sugimoto J, Yang H, Fredland A. In: Postoperative hypoparathyroidism: Diagnosis and management. Surgery of the Thyroid and Parathyroid Glands. Kaplan EL, editor. New York: Churchill Livingstone; 1983: 262-74.
15. Psarras A., Papadopoulos SN, Livadas D., Pharmakiotis AD, Koutras DA. The single thyroid nodule. *The British Journal of Surgery*. 1972; 59(7)[DOI](#)
16. Nanthakrishnan N, Rao KM, Narasimhan R, Veliath AJ. The single thyroid nodule - A South Indian Profile of 503 patients with special reference to incidence of malignancy. *Ind J Surg*. 1993;55:487-92..
17. Chaudhary M, Baisakhiya N, Singh G. Clinicopathological and Radiological Study of Thyroid Swelling. *Indian Journal of Otolaryngology and Head & Neck Surgery*. 2019; 71(Suppl 1)[DOI](#)
18. Bhansali SK. Solitary nodule in the thyroid gland; experience with 600 cases. *Ind J Surg*. 1982;44:547-6.
19. Gharib H, Papini E, Valcavi R, Baskin HJ, Crescenzi A, Dottorini ME, Duick DS, et al. American Association of Clinical Endocrinologists and Associazione Medici Endocrinologi medical guidelines for clinical practice for the diagnosis and management of thyroid nodules. *Endocrine Practice: Official Journal of the American College of Endocrinology and the American Association of Clinical Endocrinologists*. 2006; 12(1)[DOI](#)
20. Tamimi DM. Value of routine frozen section diagnosis of thyroid lesions. *Saudi Medical Journal*. 2001; 22(11)
21. Sekkath Veedu J, Wang K, Lei F, Chen Q, Huang B, Mathew A. Trends in thyroid cancer incidence in India. *Journal of Clinical Oncology*. 2018;36(15\_suppl):e18095-e18095..
22. Fenton C. L., Patel A., Burch H. B., Tuttle R. M., Francis G. L.. Nuclear localization of thyroid transcription factor-1 correlates with serum thyrotropin activity and may be increased in differentiated thyroid carcinomas with aggressive clinical course. *Annals of Clinical and Laboratory Science*. 2001; 31(3)
23. Ordóñez N. G.. Thyroid transcription factor-1 is a marker of lung and thyroid carcinomas. *Advances in Anatomic Pathology*. 2000; 7(2)[DOI](#)
24. Cheung C. C., Ezzat S., Freeman J. L., Rosen I. B., Asa S. L.. Immunohistochemical diagnosis of papillary thyroid carcinoma. *Modern Pathology: An Official Journal of the United States and Canadian Academy of Pathology, Inc*. 2001; 14(4)[DOI](#)
25. Ros P., Rossi D. L., Acebrón A., Santisteban P.. Thyroid-specific gene expression in the multi-step process of thyroid carcinogenesis. *Biochimie*. 1999; 81(4)[DOI](#)