

Diagnostic Performance of Ultra Sonography in Evaluation of Thyroid Nodule Using ATA Thyroid Nodule Sonographic Patterns and Quantitative Doppler Parameters and Correlation with FNAC

Aruna Devi Mandugula¹, Yasani Bharath Reddy¹, DR. N. Bala krishna²

¹Associate Professor, Department of Radiology Nizam's Institute of Medical Sciences, Punjagutta, Hyderabad, Telangana, India.

²HOD, Department of Statistics, AHERF Former Scientist E (Dy. Director) National Institute of Nutrition Hyderabad, India.

Abstract

Background: Thyroid nodule is common endocrine disease. FNAC is gold standard but not sensitive test. Ultrasonography features are known for risk stratification of thyroid nodule, and identifying which nodules can be triaged for repeat FNAC after negative FNA results as well. Many ultrasound risk stratification classifications of thyroid nodule are existing. But, none of these classification systems have been widely adopted worldwide due to their inherent limitations. Hence scientific data on USG thyroid needs updation to enhance the diagnostic performance of ultrasonography. **Aims and Objectives:** To assess the diagnostic performance of Grayscale sonography using ATA thyroid nodule sonographic patterns; and doppler sonography using spectral doppler parameters, i.e., RI and PI alone and in combination in determining benign and malignant thyroid nodule compared to gold standard FNAC. **Materials and Methods:** Prospective Observational Cross sectional diagnostic study. On all patients gray scale HRUS, Doppler sonography performed. Resistance Index (RI) and Pulsatility Index (PI) were assessed with spectral doppler technique. **Results and Summary:** In our study diagnostic performance of quantitative doppler parameters, i.e., RI and PI evaluated with ROC analysis revealed RI (AUC -0.813) is better predictor for malignancy than PI (AUC -0.788). An optimum cutoff of RI is >0.67. with good sensitivity 73.7%, specificity 81.2%, PPV 60.90%, NPV 88.6% to distinguish malignant from benign lesion. **Conclusion:** In our study quantitative doppler parameter, i.e., RI alone showed higher diagnostic performance to distinguish malignant from benign lesion compared to gray scale sonography and combined gray scale and doppler sonography.

Keywords: Thyroid nodule- Gray scale sonography- USG features- Doppler sonography- ATA thyroid sonographic patterns

Asian Pac J Cancer Nursing, 163-169

Submission Date: 09/20/2025 Acceptance Date: 11/07/2025

Introduction

Thyroid diseases are commonest endocrine disorder worldwide [1]. Various pathologies affect the gland are benign (colloid nodule, Hashimoto's thyroiditis, simple or hemorrhagic cyst, follicular adenoma and subacute thyroiditis) and malignant (Papillary Cancer, Follicular Cancer, Hurthle Cell (oncocytic) Cancer, Anaplastic Cancer, Medullary Cancer, Thyroid Lymphoma and metastases [2]. Most common presentation of the many of the thyroid pathologies is goiter or nodule [2]. A discrete swelling (nodule) in one lobe with no palpable abnormality elsewhere is termed an isolated or solitary swelling. Discrete

swellings with evidence of abnormality elsewhere in the gland are termed dominant. The importance of discrete swellings lies in the risk of neoplasia compared with other thyroid swellings. About 20% of isolated swellings prove to be malignant, about 30-40% are follicular adenomas. The remainder are non-neoplastic largely consisting of areas of colloid degeneration. Majority of the thyroid nodules are asymptomatic, incidentally discovered with various imaging procedures done for investigation of an unrelated condition. Incidental thyroid nodules are being diagnosed with increasing frequency in the recent years

Corresponding Author:

Dr. Aruna Devi Mandugula

Associate Professor Department of Radiology Nizam's Institute of Medical Sciences, Punjagutta, Hyderabad, Telangana, India.

Email: Aruna.Mandugula@gmail.com

due to increased use of imaging [3-5]. Thyroid nodules are common, seen in about 8.5% of the population [3]. Thyroid nodule can be palpable or nonpalpable, solitary or dominant. Palpable thyroid nodules occur only in 4-7 percent population [3, 6]. Majority of the nodules are cystic in nature, and are hyperplastic nodules that have undergone liquefactive degeneration. The clinical importance of thyroid nodules is related to excluding malignancy (4.0 to 6.5% of all thyroid nodules), evaluate their functional status and assess for the presence of pressure symptoms [3]. Thyroid cancer incidence rates are increasing in high income countries [7]. Age standardised incidence rates of thyroid cancer Globally in 2020 as per Globocon database for 185 countries by sex and 18 age groups are 10.1 per 100 000 women and 3.1 per 100 000 men, highest noted in south korea, i.e., 45 per 100 000 [8]. Hence all the thyroid nodules >1 cm need evaluation irrespective of palpability [3]. Nodules that are below 1 cm need to be evaluated based on individual risk [3]. The prognosis of thyroid cancer depend on the tumour type and its stage at the time of diagnosis [9, 10]. The prognosis for thyroid cancers such as PTC and FTC is excellent, since they are microscopic, indolent and are stable [2, 9, 10]. The 5-year relative survival is 98.6% overall, 99.9% for localized cancers, i.e., PTC and FTC [7]. Though the aggressive tumours such as MTC, DHGTC, PDTTC, HGTMTC are lethal require more intense treatment[11, 12]. the most thyroid cancer related deaths are from papillary, follicular, and Hürthle cell carcinomas since differentiated thyroid carcinomas represent more than 95% of all cases [11]. Hence, whenever a patient presents with a thyroid swelling, the task of the clinician is to distinguish the benign nodule from the malignant one. This is difficult task, and no test is perfect in this regard [3]. Various procedures in use to establish tissue diagnosis of lesions are fine needle aspiration cytology (FNAC), core needle biopsy (CNB), or excision biopsy and histopathology. FNAC is the first line diagnostic technique for thyroid nodules since decades. It is simple, safe, inexpensive, and has high diagnostic accuracy (97%). Limitations of the FNAC are cannot distinguish follicular carcinoma from follicular adenoma. Procedure related complication rates are high with CNB and excision biopsy and histopathology.

Aims and Objectives

Aims

To evaluate the diagnostic performance of Gray scale and Doppler sonography in determining benign and malignant thyroid nodule.

Objectives

To assess the diagnostic performance of Grayscale sonography using ATA thyroid nodule sonographic patterns in determining benign and malignant thyroid nodule compared to gold standard FNAC.

To assess the diagnostic performance of combined Grayscale and doppler sonography using ATA thyroid nodule sonographic patterns and spectral doppler

parameters, i.e., RI and PI in determining malignant and benign thyroid nodules compared to gold standard FNAC.

Materials and Methods

Study design: Prospective Observational Cross sectional, Diagnostic accuracy study

Location: Dept. of Radiology and Imageology, Nizam's Institute of Medical Sciences.

Period of recruitment: Nov 2020- June 2024

Participants:

- All the patients >17yrs age referred to radiology department with clinical suspicion of palpable or non-palpable thyroid lesions irrespective of sex.

- Patients with incidentally detected thyroid nodules.

- Ethics committee approval code.

Nizams Institutional Ethics Committee Approval.

Review Letter NO.EC/ NIMS/2715/2021

ESGS NO. 1117/2021.

Follow up: All the lesions were followed up with FNAC and Histo pathology examination.

Data collection: Name, Age, Gender, Patient history, Clinical symptoms, Gray scale USG appearances, Doppler Sonography parameters, HPE diagnosis.

Eligibility criteria:

- All the patients >17yrs age referred to radiology department with clinical suspicion of palpable or non-palpable thyroid lesions irrespective of sex and subsequent HPE.

- Patients with incidentally detected thyroid nodules and subsequent HPE.

- Patients who give written informed consent.

Variables: Age, Gender, Gray scale sonography, Combined Gray scale +Doppler sonography, RI, PI, SPSS version-24 was used for statistical analysis.

Statistical methods: Mean and SD were calculated for quantitative variables like Age, RI and PI.

Frequencies and percentage are calculated for Age, gender, lesion,.

t-test used for calculation of mean age of benign and mean age of malignant lesions; comparison of mean values of RI and PI.

Chi square test was used to study the association between Age groups and type of lesion

ROC curves used to generate best cut off value of RI and PI, and to estimate sensitivity, specificity and AUC to calculate the better predictor for malignancy.

Sensitivity, Specificity, PPV, NPV, Accuracy, AUC were calculated for estimation of diagnostic performance of a test.

P-value was considered as 0.05

Chi-square used to compare the observed results with expected results, i.e., USG+DOPPLER results with HPE results. The kappa value suggests level of agreement between test and gold standard (in our study HPE).

Imaging Technique

On all the patients gray scale HRUS, Doppler sonography performed with esaote My lab 9 ultrasound unit using a high frequency linear transducer (7.5 - 15

MHz), with use of various signal processing techniques, i.e. are Spatial compounding imaging, speckle reduction technique, Harmonic imaging technique. Speed of sound imaging, Extended field of view. Doppler sonography of nodules done with following machine setting - G.76% , High Pulse repetition frequency (PRF) 2.1KHz, wall filter (WF) usually 50Hz -100Hz and gate size involving the central 2/3 of vessel. Scan performed with patients lie in the supine position with the neck extended. A small pad is placed under the shoulders to provide better exposure of the thyroid gland. The thyroid gland is examined thoroughly in both transverse and longitudinal planes [13].

Image Analysis

Normal appearances of the gland: The normal thyroid gland is uniformly hyperechoic. Gray scale features used for assessment of nodule are: size, shape, margins, peripheral hypoechoic halo, composition, echogenicity, echogenic foci and calcifications [14, 15]. Doppler sonography features used for assessment are: Vascularity (central, peripheral), RI & PI. all the lesions were categorized into benign and malignant according to ATA US classification.

Nodule composition is described as solid, cystic or mixed (if the cystic component occupied an area of less than 25%, it was considered as solid; between 25 and 74% as mixed; and 75 and 100% as cystic). The nodule borders are described as smooth or irregular. Shape of the nodules is described as taller than the width and wider than the depth. Calcifications are described as no calcification, microcalcifications (≤ 2 mm), peripheral rim calcifications (continuous vs discontinuous) and macrocalcifications (> 2 mm). The peripheral halo is described as present or absent. Echogenicity is described as hypoechoic, hyperechoic, or mixed when compared to the normal thyroid parenchyma. Echogenic foci are described as hyperechoic foci with comet tail artefacts. Vascularity is described as peripheral, peripheral & central, central,

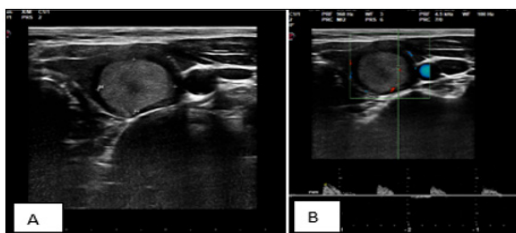


Figure 1. ATA Thyroid Nodule Sonographic Pattern - High Suspicious for Malignancy. Pathological diagnosis was Malignancy – Bethesda V.

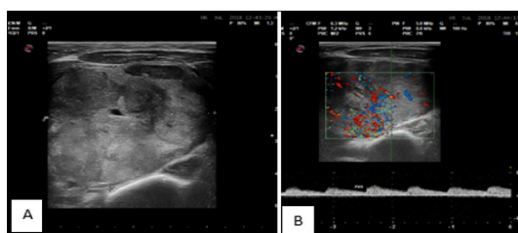


Figure 2. ATA Thyroid Nodule Sonographic Pattern-Intermediate Suspicious Lesion. Pathological diagnosis Follicular neoplasm – Bethesda-IV.

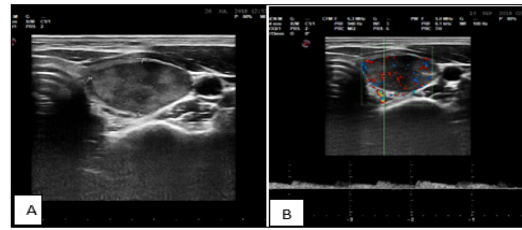


Figure 3 ATA Thyroid Nodule Sonographic Patterns Intermediate Suspicious Lesion. Pathological diagnosis Follicular lesion of unknown significance – Bethesda – III.

central with associated peripheral vascular arc. Spectral doppler findings are described as RI value of ≥ 0.70 considered as increased likelihood of malignancy and $RI < 0.70$ increased likelihood of benign. Similarly, the nodules which showed $PI \geq 1.3$ increased likelihood of malignancy and $PI < 1.3$ as increased likelihood of benign. Ultrasound machine estimates the Resistive Index (RI) and pulsatility index (PI) values with use of inbuilt software.

ATA patterns of sonographic features and risk of malignancy [14].

High suspicion [malignancy risk $>70\%$ - 90%]

Solid hypoechoic nodule or a solid hypoechoic component in a partially cystic nodule with one or more of the following features: irregular margins (specifically defined as infiltrative, micro-lobulated, or spiculated), microcalcifications, taller than wide shape, disrupted rim calcifications with small extrusive hypoechoic soft tissue component, or evidence of extrathyroidal extension. Consider FNA at ≥ 1 cm [16-20] (Figure 1).

Intermediate suspicion [malignancy risk 10% - 20%]

Solid hypoechoic nodule with smooth irregular margin, but without micro-calcifications, extrathyroidal extension, or taller than wide shape. Consider FNA at ≥ 1 cm. (Figure 2 and Figure 3).

Low suspicion [malignancy risk 5% - 10%]

Isoechoic or hyperechoic solid nodule, or partially cystic nodule with eccentric uniformly solid areas without micro-calcifications, irregular margin, or extrathyroidal extension, or taller than wide shape. Consider FNA at ≥ 1.5 cm (Figure 4).

Very low suspicion [$<3\%$]:

Spongiform or partially cystic nodule without any of the sonographic features described in the low, intermediate, or high suspicion patterns. Consider FNA at ≥ 2 cm, observation without FNA is also a reasonable option (Figure 5 and Figure 6)

BENIGN [$< 1\%$]:

Purely cystic nodules are very unlikely to be malignant.

Table 1. Showing Number of FNAC /HPE Proven Benign and Malignant Lesions

Lesion type	No. of lesions	Percent
Benign	48	71.6
Malignant	19	28.4
Total	67	100

No biopsy indicated [19, 20].

Inclusion Criteria:

All the patients with palpable thyroid nodules with or without symptoms

Symptomatic patients with Non-palpable lesions detected on diagnostic ultrasound.

Patients with asymptomatic lesions incidentally detected on neck imaging for other indication.

Exclusion Criteria:

Cases undergoing treatment.

Cases received treatment and on follow up.

Patients without FNAC / HPE diagnosis.

Patients who are not willing to give informed consent.

Results

Statistical Analysis

A total of 67 patients were included in our study. Out of 67 patients; females are 53 (79.1%), males are 14 (20.9%). Out of 67 nodules, 48 (71.6%) are histopathology proven benign nodules, 19 (28.4%) are histopathology proven malignant nodules (Table 1). Mean age was significantly ($p<0.001$) higher in malignant (49.8 ± 15.43) than Benign lesion (47.08 ± 12.86) using 't' test. Out of 48 benign nodules 39 (81%) nodules were in females; 9 (18.8%) nodules were in males. Out of 19 malignant nodules 14 (73.7%) nodules were in females; 5 (26.3%) nodules were in males (Table 4). Statistical analysis revealed there is no association between gender and lesion type ($p=0.492$). Among 67 patients; maximum number of patients 19 (28.40%) were in 41-50 years age group, followed by 31-40 years age group 17 (25.4%) (Table 2, Table 3, Table 4). Statistical analysis revealed no Association between age group and lesion type ($p=0.911$) (Table 3) Association between age range and benign lesions is (25-77). Association between age range and malignant lesions is (21-71). In all age groups Benign lesions are more frequent compared to malignant ones (Table 3).

Table 2. Lesion Frequency by Age and Gender

Patient's Age Group (in Years)	M (%)	F (%)	Total	Percentage
21-30	2 (33.33)	4 (66.66)	6	9
31-40	2 (11.76)	15 (88.24)	17	25.40
41-50	4 (21.05)	15 (78.95)	19	28.40
51-60	3 (27.27)	8 (72.72)	11	16.40
61-70	2 (18.18)	9 (81.81)	11	16.40
71-80	1 (33.33)	2 (66.66)	3	4.50
Total	14 (20.90)	53 (79.10)	67	100

Maximum number of lesions 19 (28.4%) noted in 41-50 years age group, followed by 31-40years 17 (25.4%). Lesion frequency is more in females in all age groups compared to males.

Table 3. Frequency of Lesion Type by Age

			HPE		Total
			Benign	Malignant	
Age Group	21-30	Count	4	2	6
		%	66.66	33.33	9.00
	31-40	Count	14	3	17
		%	82.35	17.65	25.40
	41-50	Count	13	6	19
		%	68.42	31.58	28.40
	51-60	Count	8	3	11
		%	72.72	27.27	16.40
	61-70	Count	7	4	11
		%	63.63	36.36	16.40
	71-80	Count	2	1	3
		%	66.66	33.33	4.50
	Total	Count	48	19	67
		%	100.00	100.00	100.00

Benign lesions are more frequent in all age groups compared to malignant ones. Benign nodules more frequent (29.17%) in 31-40year age group. Malignant nodules are more frequent (36.36%) in 61-70 year age group.

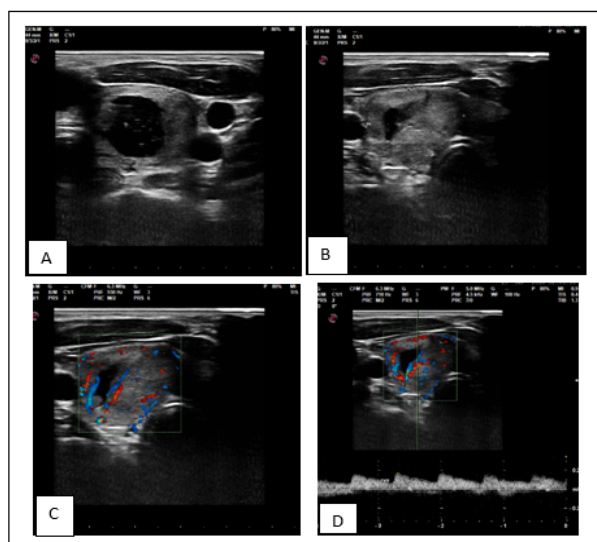


Figure 4. ATA Thyroid Nodule Sonographic Pattern - Low Suspicious for Malignancy. FNAC diagnosis - Adenomatous nodule - Bethesda II.

Cumulative percent of benign lesions is 71.6%. Benign nodules more frequent (29.17%) in 31-40year age group. Statistical analysis revealed no Association between age group and lesion type ($p=0.911$). Lesion frequency is more in female population in all age groups compared to males (Table 4). In our study evaluation of diagnostic performance of quantitative doppler parameters, i.e., RI and PI with ROC analysis revealed optimum cutoff of RI to determine malignant lesions is >0.67 with sensitivity of 73.7%, specificity 81.2%, PPV 60.90%, NPV 88.6%. Optimum cutoff of PI to determine malignant lesions is >0.9 with sensitivity of 94.7%, specificity 60.4%, PPV 48.60%, NPV 96.70%. Both RI and PI show statistical significance ($p\text{-value}<0.0001$). AUC calculation with ROC curve analysis revealed RI is better predictor for malignancy than PI since area under curve of RI is (AUC -0.813) is larger than PI (AUC -0.788). In our study evaluation of diagnostic performance of Grayscale sonography using ATA thyroid nodule sonographic patterns in determining benign Vs malignant thyroid nodules compared to gold standard FNAC /HPE revealed (Supplementary Table 1): Out of 67 nodules, 30 (44.78%) were benign, 37 (55.22%) were malignant. 26 (86.67%) out of 30 benign nodules showed correlation with FNAC. 15 (40.54%) out of 37 malignant nodules showed correlation with FNAC. Diagnostic test calculation revealed sensitivity (78.95%), specificity (54.17%), PPV

(40.54%), NPV (86.66%), accuracy 61.19%. Evaluation of Diagnostic performance of combined Grayscale and Doppler sonography (Supplementary Table 1) in differentiating malignant from benign thyroid nodules using ATA thyroid nodule sonographic patterns and quantitative doppler parameter RI revealed: Out of 64 nodules 25 (37.31%) were benign, 42 (62.69%) were malignant. Out of 25 benign nodules 23 (92%) nodules showed correlation with HPE. Out of 42 malignant nodules 17 (40.48%) showed correlation with HPE with sensitivity 89.47%, specificity 47.92%, PPV40.48%, NPV92.00% with an accuracy of 59.70%.

Discussion

American thyroid association ATA patterns of sonographic features are complex but are evidence based recommendations which include initial evaluation of nodule, clinical and ultrasound criteria for fine-needle aspiration biopsy, interpretation of fine-needle aspiration biopsy results, use of molecular markers, and management of benign and malignant thyroid nodules. And major goal of ATA patterns of sonographic features is to minimize potential harm from over treatment in majority of patients at low risk for disease-specific mortality and morbidity, while appropriately treating and monitoring those patients at higher risk.

In our study evaluation of diagnostic performance of Gray scale sonography using ATA thyroid nodule sonographic patterns in determining benign Vs malignant thyroid nodules compared to gold standard FNAC / HPE revealed (Supplementary Table 1) revealed good sensitivity (78.95%), moderate specificity (54.17%), poor PPV (40.54%), good NPV (86.66%), accuracy 61.2% with fair agreement with gold standard ($\kappa=0.257$) - No similar study found in published scientific data.

In our study evaluation of diagnostic performance of

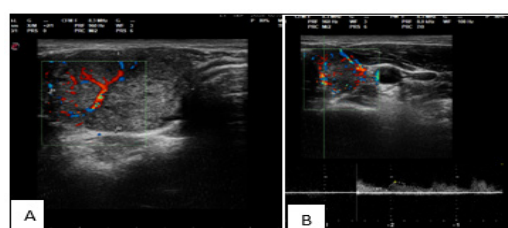


Figure 5. ATA Thyroid Nodule Sonographic Pattern - Low Suspicious. Pathological diagnosis - Adenomatous nodule - Bethesda - II.

Table 4. Gender Distribution of Benign and Malignant Lesions

			HPE		Total
			Benign	Malignant	
Sex	Female	Count	39	14	53
		%	81.30	73.70	79.10
	Male	Count	9	5	14
		%	18.80	26.30	20.90
Total		Count	48 (71.64%)	19 (28.36%)	67

Out of 48 benign nodules 39 (81%) nodules were in females; 9 (18.8%) nodules were in males. Out of 19 malignant nodules 14 (73.7%) nodules were in females; 5 (26.3%) nodules were in males.

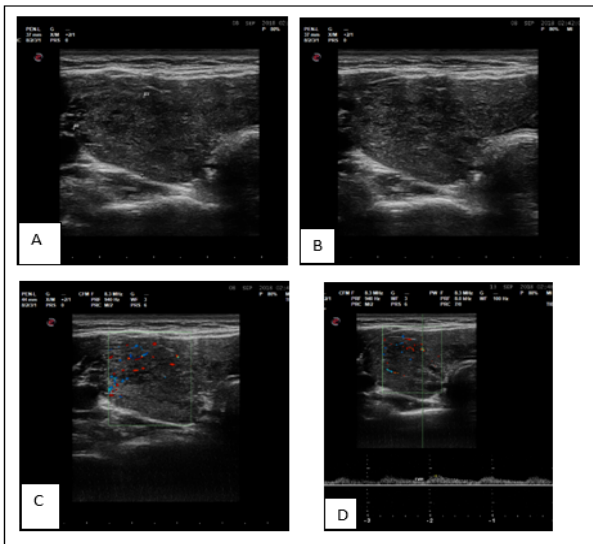


Figure 6. ATA Thyroid Nodule Sonographic Patterns - Low Suspicious. Pathological diagnosis - Hashimoto's thyroiditis - Bethesda II.

quantitative doppler parameters RI, and PI in determining malignant Vs benign lesions with ROC curve analysis revealed optimum cut off of RI to determine malignant lesions is >0.67 with sensitivity of 73.7%, specificity 81.2%. Optimum cut off of PI to determine malignant lesions is >0.9 with sensitivity of 94.7%, specificity 60.4%. Both RI and PI show statistical significance (p -value <0.0001). AUC of RI is larger (0.813) than the PI. hence, better predictor of lesion than PI.

Our study results are in concordance with study done by Saeed Kalantari, In their study on 63 patients concluded there is significant association between Resistive Index and Pulsatility Index with malignancy with a cutoff of RI ≥ 0.715 ($P=0.005$) and PI ≥ 0.945 ($P=0.007$) [21]. Manoj Kumar Palaniappan et al. [22] In their study on 194 nodules revealed best cut off of RI greater than 0.73, best cut off of PI greater than 1.3 to differentiate malignant from benign. Sensitivity, and specificity of spectral doppler in differentiating benign vs malignant lesions revealed 76.78%, and 81.7% respectively.

Evaluation of diagnostic performance of combined Gray scale and Doppler sonography using ATA thyroid nodule sonographic patterns and quantitative doppler parameters (RI, PI): ATA+RI revealed good sensitivity (89.47%), poor specificity (47.92%), poor PPV (40.48%) and good NPV (92.00%), with diagnostic accuracy of 59.70% with fair agreement with gold standard Kappa= 0.274 (Supplementary Table 1). Compared to Gray scale sonography using ATA patterns of sonographic features there is mild increase in sensitivity at the cost of mild decrease in specificity with fair agreement with gold standard. No similar study found in published data.

In conclusion, in our study evaluation of diagnostic performance of quantitative doppler parameters RI, and PI in determining malignant Vs benign lesions with ROC curve analysis revealed RI is better predictor of lesion than PI (AUC of RI -0.813 larger than PI) with highest sensitivity. Specificity 73.7%, 81.2%.

Evaluation of diagnostic performance of combined

Gray scale and Doppler sonography with use of ATA thyroid nodule sonographic patterns and quantitative doppler parameter, i.e., RI revealed No added advantage of doppler.

Limitations

Doppler sonography is operator and machinery settings dependent.

Sample size is small and needs studies with larger data to validate our study result.

Acknowledgments

Statement of Transparency and Principals:

- Author declares no conflict of interest
- Study was approved by Research Ethic Committee of author affiliated Institute.
- Study's data is available upon a reasonable request.
- All authors have contributed to implementation of this research.

References

1. Unnikrishnan AG, Menon UV. Thyroid disorders in India: An epidemiological perspective. *Indian Journal of Endocrinology and Metabolism*. 2011 07;15(Suppl 2):S78-81. <https://doi.org/10.4103/2230-8210.83329>
2. Tamhane S, Gharib H. Thyroid nodule update on diagnosis and management. *Clinical Diabetes and Endocrinology*. 2016;2:17. <https://doi.org/10.1186/s40842-016-0035-7>
3. Unnikrishnan AG, Kalra S, Baruah M, Nair G, Nair V, Bantwal G, Sahay RK. Endocrine Society of India management guidelines for patients with thyroid nodules: A position statement. *Indian Journal of Endocrinology and Metabolism*. 2011 01;15(1):2-8. <https://doi.org/10.4103/2230-8210.77566>
4. NCBI Book shelf. Ahmet S. Can; Anis Rehman.
5. Mathew IE, Mathew A. Rising Thyroid Cancer Incidence in Southern India: An Epidemic of Overdiagnosis?. *Journal of the Endocrine Society*. 2017 05 01;1(5):480-487. <https://doi.org/10.1210/js.2017-00097>
6. Welker MJ, Orlov D. Thyroid nodules. *American Family Physician*. 2003 02 01;67(3):559-566. <https://doi.org/JJJJ>
7. Kitahara CM, Schneider AB. Epidemiology of Thyroid Cancer. *Cancer Epidemiology, Biomarkers & Prevention: A Publication of the American Association for Cancer Research, Cosponsored by the American Society of Preventive Oncology*. 2022 07 01;31(7):1284-1297. <https://doi.org/10.1158/1055-9965.EPI-21-1440>
8. Pizzato M, Li M, Vignat J, Laversanne M, Singh D, La Vecchia C, Vaccarella S. The epidemiological landscape of thyroid cancer worldwide: GLOBOCAN estimates for incidence and mortality rates in 2020. *The Lancet. Diabetes & Endocrinology*. 2022 04;10(4):264-272. [https://doi.org/10.1016/S2213-8587\(22\)00035-3](https://doi.org/10.1016/S2213-8587(22)00035-3)
9. Olson E, Wintheiser G, Wolfe KM, Droessler J, Silberstein PT. Epidemiology of Thyroid Cancer: A Review of the National Cancer Database, 2000-2013. *Cureus*. 2019 02 24;11(2):e4127. <https://doi.org/10.7759/cureus.4127>
10. Nguyen QT, Lee EJ, Huang MG, Park YI, Khullar A, Plodkowski RA. Diagnosis and treatment of patients with thyroid cancer. *American Health & Drug Benefits*. 2015 02;8(1):30-40. <https://doi.org/HHHH>
11. Haddad RI, Bischoff L, Ball D, Bernet V, Blomain E, Busaidy NL, Campbell M, et al. Thyroid Carcinoma, Version 2.2022,

- NCCN Clinical Practice Guidelines in Oncology. Journal of the National Comprehensive Cancer Network: JNCCN. 2022 08;20(8):925-951. <https://doi.org/10.6004/jnccn.2022.0040>
12. Jung CK, Bychkov A, Kakudo K. Update from the 2022 World Health Organization Classification of Thyroid Tumors: A Standardized Diagnostic Approach. *Endocrinology and Metabolism* (Seoul, Korea). 2022 Oct;37(5):703-718. <https://doi.org/10.3803/EnM.2022.1553>
 13. Loevner LA. Imaging of the thyroid gland. *Seminars in ultrasound, CT, and MR*. 1996 Dec;17(6):539-562. [https://doi.org/10.1016/s0887-2171\(96\)90003-7](https://doi.org/10.1016/s0887-2171(96)90003-7)
 14. Haugen BR, Alexander EK, Bible KC, Doherty GM, Mandel SJ, Nikiforov YE, et al. 2015 American Thyroid Association Management Guidelines for Adult Patients with Thyroid Nodules and Differentiated Thyroid Cancer: The American Thyroid Association Guidelines Task Force on Thyroid Nodules and Differentiated Thyroid Cancer. *Thyroid: Official Journal of the American Thyroid Association*. 2016 01;26(1):1-133. <https://doi.org/10.1089/thy.2015.0020>
 15. Patel BN, Kamaya A, Desser TS. Pitfalls in sonographic evaluation of thyroid abnormalities. *Seminars in ultrasound, CT, and MR*. 2013 06;34(3):226-235. <https://doi.org/10.1053/j.sult.2012.11.001>
 16. Dighe M, Barr R, Bojunga J, Cantisani V, Chammas MC, Cosgrove D, Cui XW, et al. Thyroid Ultrasound: State of the Art. Part 2 - Focal Thyroid Lesions. *Medical Ultrasonography*. 2017 04 22;19(2):195-210. <https://doi.org/10.11152/mu-999>
 17. Topaloglu O, Baser H, Cuhaci FN, Sungu N, Yalcin A, Ersoy R, Cakir B. Malignancy is associated with microcalcification and higher AP/T ratio in ultrasonography, but not with Hashimoto's thyroiditis in histopathology in patients with thyroid nodules evaluated as Bethesda Category III (AUS/FLUS) in cytology. *Endocrine*. 2016 Oct;54(1):156-168. <https://doi.org/10.1007/s12020-016-0982-x>
 18. Andrioli M, Valcavi R. Sonography of Normal and Abnormal Thyroid and Parathyroid Glands. *Frontiers of Hormone Research*. 2016;45:1-15. <https://doi.org/10.1159/000442273>
 19. Brito JP, Gionfriddo MR, Al Nofal A, Boehmer KR, Leppin AL, Reading C, Callstrom M, et al. The accuracy of thyroid nodule ultrasound to predict thyroid cancer: systematic review and meta-analysis. *The Journal of Clinical Endocrinology and Metabolism*. 2014 04;99(4):1253-1263. <https://doi.org/10.1210/jc.2013-2928>
 20. Burgos N, Ospina NS, Sipos JA. The Future of Thyroid Nodule Risk Stratification. *Endocrinology and Metabolism Clinics of North America*. 2022 06;51(2):305-321. <https://doi.org/10.1016/j.ecl.2021.12.002>
 21. Kalantari S. The Diagnostic Value of Color Doppler Ultrasonography in Predicting Thyroid Nodules Malignancy. *The International Tinnitus Journal*. 2018 06 01;22(1):35-39. <https://doi.org/10.5935/0946-5448.20180006>
 22. Palaniappan MK, Aiyappan SK, Ranga U. Role of Gray Scale, Color Doppler and Spectral Doppler in Differentiation Between Malignant and Benign Thyroid Nodules. *Journal of clinical and diagnostic research: JCDR*. 2016 08;10(8):TC01-06. <https://doi.org/10.7860/JCDR/2016/18459.8227>



This work is licensed under a Creative Commons Attribution-Non Commercial 4.0 International License.