

# Unusual Presentation of Metastasis to the Ascending Colon from Squamous Cell Carcinoma of the Cervix

Selvaluxmy Ganesarajah, Vasanth Christopher, Ram Madhavan, Vengada Krishn P.R.

Cancer Institute (WIA), Adyar, India.

## Abstract

**Background:** Metastasis to the ascending colon from primary carcinoma of the cervix is an uncommon occurrence. Squamous cell carcinoma (SCC) of the cervix can metastasize to unusual sites, including the bones, stomach, duodenum, colon, and skin. SCC of the cervix is a rare malignancy of the gastrointestinal tract (GI). Metastasis of SCC of the cervix to the GI tract is infrequent and has only been reported in a few cases. This condition can manifest as intestinal obstruction, often requiring debulking surgery. The management is typically palliative, and the role of chemotherapy or radiation therapy remains unclear. **Case Presentation:** In this report, we present the case of a 47-year-old female with a history of squamous cell carcinoma of the cervix, initially treated in 2014. She experienced local recurrence in 2019 and underwent pelvic re-radiation. Subsequently, she presented with intestinal obstruction, and further evaluation revealed metastatic squamous cell carcinoma in the ascending colon.

*Asian Pac J Cancer Care*, 8 (3), 653-654

Submission Date: 04/18/2023

Acceptance Date: 06/12/2023

## Introduction

Histologically squamous cell carcinoma (SCC) accounts for majority (70%) of all cervical cancers. Metastasis or disease progression occurs within the first two years of treatment, and is associated with poor prognosis [1]. The most common sites of metastasis are to lung or para aortic lymph nodes. Metastasis to GI tract is very uncommon. Here we discuss a case of squamous cell carcinoma of cervix with metastasis to ascending colon and liver 7 years after treatment of primary. The patient presented with intestinal obstruction and underwent surgery to debulk the tumor and relieve the obstruction. In case of unresectable masses radiotherapy may aid in ablation. The role of chemotherapy remains controversial.

### Case presentation

47 year old female was diagnosed to have squamous cell carcinoma of uterine cervix stage III.B in 2014 and treated with chemoradiation and developed local recurrence in 2019 for which she received re-radiation. She then presented in 2021 with symptoms of pain abdomen, vomiting, obstipation which was clinically

suspicious of acute intestinal obstruction.

CT Abdomen and pelvis (Figure 1 and 2) revealed circumferential wall thickening involving proximal ascending colon causing luminal narrowing along with hypodense lesions in liver highly suspicious of metastasis.

Patient underwent laparotomy and proceeded to right hemi colectomy and liver metastasectomy. Intra operatively mass noted in the segment VI of liver extending to ascending colon causing extrinsic compression and densely adherent to 2<sup>nd</sup> part of duodenum and right kidney, separate liver nodule in segment VI of liver infiltrating right diaphragm with extension to pleura noted.

Histopathology of the Specimen (Figure 3) revealed colonic tissue entirely infiltrated by nests and sheets of atypical squamous cells with cells showing moderate cytoplasm and hyper chromatic nuclei suggestive of metastatic squamous cell carcinoma of colon and liver 12 out of 13 lymph nodes dissected showed metastatic squamous cell carcinoma with presence of lymphatic tumor emboli and perinodal spread.

Patient was planned for palliative chemotherapy. Received 3 cycles of Paclitaxel and carboplatin

### Corresponding Author:

Dr. Vengada Krishn P.R.

Cancer Institute (WIA), Adyar, India.

Email: vengadakrishnan@gmail.com

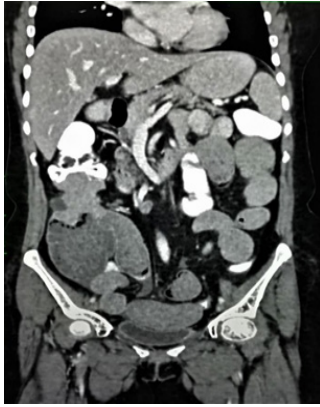

Figure 1. Contrast Enhanced CT Abdomen and Pelvis in Coronal Plane Shows Wall Thickening Involving Proximal Ascending Colon Causing Luminal Narrowing with Proximally Dilated Cecum.

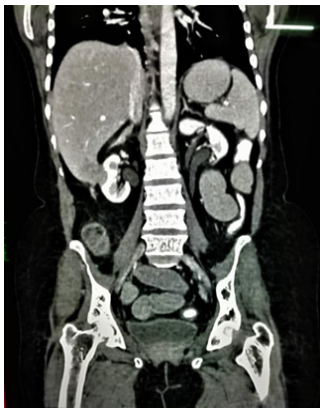

Figure 2. Contrast Enhanced Coronal Image of Abdomen Shows Hypo Dense Areas of Washout Noted in Segment VI of Liver with Infiltration of Right Kidney

chemotherapy. Post 3 cycles of palliative chemotherapy, disease progressed and hence further chemotherapy was deferred and offered best supportive care.

## Discussion

The incidence of distant metastasis in carcinoma cervix is around 35% [2], the most common sites being

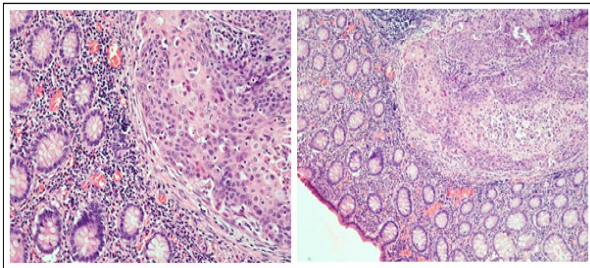


Figure 3. Histopathology of the Specimen Revealed colonic Tissue Entirely Infiltrated by Nests and Sheets of Atypical Squamous Cells with Cells Showing Moderate Cytoplasm and Hyper Chromatic Nuclei Suggestive of Metastatic Squamous Cell Carcinoma of Colon and Liver.

the lungs and para aortic lymph nodes. Metastasis to the gastrointestinal tract is extremely uncommon. Metastasis to colon have been reported from carcinoma breast, ovary, melanoma [3, 4].

Metastasis to the colon from any malignancy can occur through trans celomic, hematogenous, retrograde lymphatic or trans luminal passages [5].

Most reports of secondary tumors in the colon metastasized in the form of peritoneal seedlings.

This patient had pelvic re-radiation 2 years back and presented with signs of acute abdomen which was suspicious of perforation or peritonitis. The incidence of late GI toxicity post pelvic radiation is established. This patient had received radiation to pelvis twice and has high chance of developing late bowel toxicity [6]. Though the clinical picture mimics perforation, imaging was suggestive of mass in the ascending colon causing obstruction. Increase in survival of patients with carcinoma cervix has also attributed to distant metastasis and such rarer sites of metastasis.

Metastasis to ascending colon has poor prognosis due to its advanced nature and late presentation. The management remains controversial as the number of cases reported are few. It requires debulking which may relieve obstruction and improve the quality of life. The role of chemotherapy and radiation depends on the performance status of the patient. Further studies are needed to compare the outcome of different modalities of management.

## References

1. Lelchuk A, Morin N, Bain K. Squamous cell carcinoma of cervix origin with rare metastasis to the colon. AME case reports. 2018;2:23. <https://doi.org/10.21037/acr.2018.05.02>
2. Hong JH, Tsai CS, Lai CH, Chang TC, Wang CC, Chou HH, Lee SP, Hsueh S. Recurrent squamous cell carcinoma of cervix after definitive radiotherapy. International Journal of Radiation Oncology, Biology, Physics. 2004 09 01;60(1):249-257. <https://doi.org/10.1016/j.ijrobp.2004.02.044>
3. Leung KK, Heitzman J, Madan A. Squamous cell carcinoma of the rectum 21 years after radiotherapy for cervical carcinoma. Saudi Journal of Gastroenterology: Official Journal of the Saudi Gastroenterology Association. 2009;15(3):196-198. <https://doi.org/10.4103/1319-3767.54745>
4. Ganesh MS, Ayyappan S, Majhi U. Squamous cell carcinoma of ascending colon. A case study. Indian Journal of Cancer. 1999;36(2-4):190-191.
5. McMahon AJ. Squamous carcinoma of the colon: primary or metastatic?. European Journal of Surgical Oncology: The Journal of the European Society of Surgical Oncology and the British Association of Surgical Oncology. 1991 08;17(4):397-402.
6. Kuku S, Fragkos C, McCormack M, Forbes A. Radiation-induced bowel injury: the impact of radiotherapy on survivorship after treatment for gynaecological cancers. British Journal of Cancer. 2013 09 17;109(6):1504-1512. <https://doi.org/10.1038/bjc.2013.491>



This work is licensed under a Creative Commons Attribution-Non Commercial 4.0 International License.