

Expression of Pan-cytokeratin [Ae1/Ae3] in Oral Squamous Cell Carcinoma and Potential Malignant Oral Disorders- A Comparative Systematic Review

Nanda Kumar H, Madhu Narayan, Krishnan Rajkumar, V Vasanthi

Department of Oral Pathology, India.

Abstract

Introduction: Intermediate filament and its prime role in the cytoskeleton involved in maintaining cell morphology, and is mainly observed in epithelial cells called as Cytokeratin. CKAE1/AE3 is a combination of two different clones of anti-CK monoclonal antibodies, a single reagent can be obtained with broad spectrum reactivity to high molecular weight and low molecular weight CK which can be used in different types of cancers or lesions. **Aim:** To compare the expression of the CK-AE1/AE3 in oral squamous cell carcinoma (OSCC) and potentially malignant oral disorders (PMOD) through immunohistochemical method through a systematic review process. **Materials and Methods:** Articles or original studies related to the use of IHC marker AE1/AE3 in OSCC, malignant tumors and PMODs were selected for systematic review process. PUBMED and GOOGLE SCHOLAR were the search engines used for collection of articles. Keywords used were PAN CK [AE1/AE3], SCC, OSCC, PMOD. Articles included based on PRISMA guidelines. **Results:** A total article based on search strategy identified 492 suitable abstracts; 474 did not meet the eligibility criteria. Full text articles were obtained for 18 articles. Six articles were excluded from the study for various reasons like case reports, reviews and letters to editors and any article published in languages other than English were also excluded. Finally, after considering all the inclusion and exclusion criteria, a total of 12 articles were included in the study. Considering all these articles, comparing the expression of pan-cytokeratin [ae1/ae3] in oral squamous cell carcinoma and potential malignant oral disorders.

Keywords: Pan-Cytokeratin [AE1/AE3]- OSCC- PMOD

Asian Pac J Cancer Care, 7 (2), 357-362

Submission Date: 01/05/2022 Acceptance Date: 04/15/2022

Introduction

Squamous cell carcinoma accounts for 90% of all oral malignant growths. It can affect any anatomical part of the mouth, but the most common are the tongue and the floor of the mouth. It usually comes from pre-existing potentially malignant lesions and sometimes can arise as an entirely new lesion; but in any case, it comes from the precancerous epithelium. well-known risk factors for oral squamous cell carcinoma are Tobacco and betel quid use, excessive consumption of alcoholic beverages, and low intake of fresh fruits and vegetables [1].

The term "Potential Malignant Oral Disorder" (OPMD) was recommended by an international working group convened in London in 2005 by the World Health

Organization (WHO) Collaborating Center for Oral Cancer and Precancerous Diseases. This suggests that not all diseases described as such will transform into invasive cancer. Leukoplakia, erythroplakia, oral submucosal fibrosis, lichen planus, palatal lesions in reverse smokers, actinic keratosis, discoid lupus erythematosus, congenital dyskeratosis, and epidermolysis bullosa are examples of potentially malignant oral disorders [2].

Cytokeratin (CK) is an intermediate filament and is an important part of the cytoskeleton involved in maintaining cell morphology, and is mainly observed in epithelial cells. CKAE1/AE3 is a mixture of two different clones of anti-CK monoclonal antibodies. By combining these two

Corresponding Author:

Dr. Nanda Kumar H
Department of Oral Pathology, India.
Email: dr.nandakumar1997@gmail.com

reagents, a single reagent with broad spectrum reactivity to high molecular weight and low molecular weight CK can be obtained. In a study by Kaufmann et al, in dysplasia and carcinoma in situ, atypical cells show a response pattern in which there is loss or increased expression of AE1, which indicates that AE1 can be used as a biomarker to identify early aberrations in esophageal epithelial cancer [3].

This study is to compare the expression of the CK-AE1/AE3 in oral squamous cell carcinoma (OSCC) and potentially malignant oral disorders (PMOD) through immunohistochemical method through a systematic review process.

Materials and Methods

In this study, a systematic review has been performed by considering AE1/AE3 as a diagnostic histochemical marker in both OSCC and PMOD.

To answer the question of whether AE1/AE3 can be used as a diagnostic marker in PMODs, the literature search using a combination of keywords was done. PUBMED and GOOGLE SCHOLAR were the search engines that were used for collection of articles. Keywords used were PAN CK [AE1/AE3], SCC, OSCC, PMOD. Only invitro studies conducted in humans for the past 15 years were included in the study.

Inclusion Criteria

1. ORIGINAL STUDY related to the use of IHC marker AE1/AE3 in OSCC, malignant tumors and PMODs.
2. Articles Published from 2005 to 2021.

Exclusion Criteria

1. Reviews, case reports, conference presentations.
2. No full text
3. Languages other than English
4. Published before 2005

The article has been written according to the PRISMA guidelines (Figure 1).

Results

The keyword search strategy identified 492 suitable abstracts; 474 did not meet the eligibility criteria. Full text articles were obtained for 18 articles. Six articles were excluded from the study for various reasons like case reports, reviews and letters to editors and any article published in languages other than English were also excluded. Finally, after considering all the inclusion and exclusion criteria, a total of 12 articles were included in the study. Five studies were taken for OSCC, four studies related to Squamous Cell Carcinoma (SCC)

Table 1. Overview of Selected Studies

S.NO	Year	Country	Author Name	Sample Size	Parameter Assessed	Observation	Inference
1	2016	India	Anand Bhadkariya et al [3]	90	CK AE1/AE3	In aspirate cytology, Immunocytochemical (ICC) detection of CK of malignant cells with or without inflammatory and benign cells. Varied patterns of CK positivity on correlating with respect to cytological diagnosis.	Malignant cells were positive about 40% cases for CK of which the most common pattern observed was diffuse cytoplasmic staining. 66.6% cases of SCC were positive for diffuse pattern over-expression of CK was observed.
2	2016	India	Isha Dhawan et al [4]	10	OSCC -CK AE1/AE3	Laboratory based, prospective study was conducted on 133 lymph nodes (LNs) harnessed from ten patients treated with radical neck dissection for primary OSCC. The LNs were subjected to serial sectioning at 100 µm intervals. The usual Haematoxylin & Eosin staining was done for sections and pan-CK and were analyzed for micrometastasis and isolated tumor cells according to criteria laid by Hermanek et al.	The SS and immunohistochemistry (IHC) combined for using pan-CK (AE1/AE3) in this study established the presence of MM and ITC in 2.25% of the LNs diagnosed as negative on routine H&E examination. The evaluation of deposition of occult metastases resulted in upstaging of 33.33% of the patients.
3	2016	India	Vineeth Gupta et al [5]	30 Biopsy Specimens	CKs	A pilot study of 15 patients clinically diagnosed with carcinoma and their paralleling mirror image sites were taken and stained using immunohistochemistry method for the CK, Ki-67 and p53 expression.	Primary tumors showed strong positive staining for CK throughout the epithelium and malignant epithelial islands but absence of staining for Ki-67 and p53
4	2018	China	Xin Min Li et al [6]	82 Primary esophageal small cell carcinoma	PANCKs	Eighty-two Primary Esophageal Small Cell carcinoma patients were identified from the esophageal and gastric cardia cancer database which was created by Henan Key Laboratory for Esophageal Cancer Research, Zhengzhou University. This retrospective study evaluated CK and vimentin protein expressions in PESC.	In cytoplasm of epithelial component tumor cells positive pan-CKs AE1/AE3 staining was evaluated, with a positive detection rate of 85.4% (70/82). AE1/AE3 positive staining seen in 19 cases, observed both in epithelial and spindle components (23.2%). However, there was no association of AE1/AE3 with factors such as gender, tumor location, age, gross appearance, lymph node metastasis and TNM staging.

Continued Table 1.

S.NO	Year	Country	Author Name	Sample Size	Parameter Assessed	Observation	Inference
5	2007	India	Ruchika Gupta et al [7]	35 Spindle cell carcinoma patients	CKs	To find out the difference in immunohistochemical expression of CK, smooth muscle actin and vimentin and alterations in mutation of K-RAS oncogene between the two tumours, in an attempt to characterise Spindle cell Carcinoma. Standard avidin-biotin complex method was used to perform IHC analysis	In the Spindle Cell Carcinoma group, CK positivity was significantly higher in epithelial areas (52.2%) than in spindle cell areas (16.1%), whereas vimentin was intense positive in spindle cell areas (18.7%) than epithelial areas (2.7%). Cells mixed between epithelial and spindle cell areas were consistently positive for both CK and vimentin.
6	2006	Europe	G Cserni et al [8]	449 patients with lobular breast carcinoma	CK	This study aimed to assess the value of CK IHC for the detection of metastases in sentinel lymph nodes of patients with invasive lobular carcinoma. The use of IHC was to find the different metastases, and the involvement of non-sentinel lymph nodes were analysed in a multi-institutional cohort of 449 patients with lobular breast carcinoma, with staging of sentinel lymph node biopsy and routine assessment of the sentinel lymph nodes.	Different type of sentinel lymph node involvement was seen in 189 patients (42%), there was increased frequency of with increasing tumour size. IHC used for identification of lymph node involvement 65 of these tumor cases: 17 of 19 isolated tumour cells, 8 of 106 larger metastases, 40 of 64 micrometastases, and were detected.
7	2020	Santo Domingo	Velicko Vranes et al [9]	102 breast carcinoma patients	CK	Prognostic model consists 102 breast carcinoma patients, along with distant metastasis occurrence as the endpoint. Complete intensity range (0-255) of pan CK digitized immunostaining was segmented into seven discrete narrow grey level ranges: 0-130, 130-160, 160-180, 180-200, 200-220, 220-240, and 240-255. 33 major (Gray Level Co-occurrence Matter), fractal and first-order statistics computational analysis features used for detection.	Moderate intensities were strongly associated with metastasis outcome; However, high intensities of pan CK immunostaining provided no prognostic value even after an exhaustive computational analysis.
8	2021	Brazil	B-T Rodrigues et al [10]	15482 biopsy specimens of primary oral melanoma	CK	A total of 15,482 biopsy records from two Oral and Maxillofacial Pathology services in Brazil were analyzed. Complete cases oral melanomas were inspected and their demographic, clinical, histopathological data, treatment, and follow-up status were collected. In addition, IHC stains (pan-CK AE1/AE3, CD45, α -SMA, vimentin, S-100 MelanA, protein, HMB-45, and Ki-67) were performed.	Cases-5 males (71.4%) and 2 females (28.6%), and 2.5:1 male-to-female ratio, mean age of 58.0 ± 9.2 years (range:45-69 years). Most commonly affected were gingiva (n = 3, 42.8%) and hard palate (n = 2, 28.6%).
9	2005	China	Zhi-Wei Zhou et al [11]	114 patients with colorectal cancer	CK	This study aimed to detect lymph nodes micrometastases and analyze its correlation with clinicopathological parameters in Dukes' A and B colorectal cancer patients. 114 patients with colorectal cancer (Dukes' A 16; Dukes' B 98) undergone curative operation without histological lymph nodes metastases were studied between 2001 and 2003. From histopathological archives, A total of 2,481 lymph node 2 481 lymph nodes were determined using monoclonal CK antibody AE1/AE3 (DAKO, Carpinteria, CA) for immunohistochemistry.	In total, 33 (29%) patients were positive for cancer cell by immunohistochemistry.
10	2004	Craiova	Mălin RD et al [12]	24 cases	CK7, CK19, CK20, CKAE1/AE3, CK34betaE12, TTF1, HBME-1, CEA, MUC5AC and EBV.	This study found that all ENT primary tumor with Lymph node metastases were positive for CKAE1/AE3; CKAE1/AE3 negativity was seen in adenocarcinomas and CKAE1/AE3 positivity in squamous carcinomas.	From the immunohistochemical point of view, the esophageal carcinoma was positive for CKAE1/AE3, while the gastric adenocarcinoma was positive for CEA.

Continued Table 1.

S.NO	Year	Country	Author Name	Sample Size	Parameter Assessed	Observation	Inference
11	2004	London	M Farrar et al [13]	10	AE1/AE3, CK [CK] 14, Ki-67 and p53	In this study, a panel of monoclonal antibodies (AE1/AE3, CK [CK] 14, Ki-67 and p53) in 10 cases of human oral tissue in each of six variants to obtain staining patterns.	The results showed that AE1/AE3 and CK 14 expression was reduced as a late event in oralcarcinogenesis, particularly in poorly differentiated SCC.Expression of Ki-67 and p53 proved to be a poor but statistically significant predictor of malignant progression.
12	2006	India	K Ranganathan et al [14]	60	PanCK AE1/AE3 (1-8, 10, 13-16 and 19)	Significant difference in the CK staining pattern was seen among normal, OSMF and cancer tissues. Significant changes in OSMF included increased intensity of staining for PanCK and High Molecular Weight Cytokeratin, CK8 abnormal expression and decreased expression of CKs 5 and 14.	CK profile of OSMF was significantly varies from normal for PanCK, HMWCK, CK8,5 and 14 suggesting the latter's potential to be used as surrogate markers of malignant transformation.

MM, Micro metastasis; ITC, isolated tumor cells; H&E, Haematoxylin and Eosin; PESC, Primary esophageal small cell carcinoma; Pan CK, Pan cytokeratin; SMA, Smooth muscle actin; HMB, human melanoma black; PCNA, Proliferating cell nuclear antigen; VEGF, Vascular endothelial growth factor; HMWCK, High molecular weight cytokeratin

occurring in other parts of the body like gastro-intestinal tract-colorectal, oesophagus and breast cancer, two for Oral Sub Mucous Fibrosis (OSMF) and one study related to leukoplakia. The different studies showed that the expression of CK [AE1/AE3] increased as the grade of the malignancy worsened, starting from the PMODs like OSMF and dysplasia to poorly differentiated SCC, corroborated by the weakly-positive staining of PMODs, positive staining by SCC and greatest intensity of immunological staining by poorly differentiated SCC (Table 1).

Discussion

In India oral tumors constitutes 30% of all malignancies and of these 90% are OSCC. Some of the oralcarcinomas arise from pre-existing,pre-cancerous lesions such as OSMF and leukoplakia. However, the malignant conversion rate of pre cancerous lesion ranges from 8% to 10%. Recently, it has been found that even the clinically normal appearing mucosa in a patient. Dysplasia may be observed in cancerous lesion and on the contra lateral anatomic site. To study histopathologic changes that are observed in mucosa opposite to oral cancers,tumor markers play an important role in differentiating a normal tissue from cancerous tissue.

Pan CK (pan CK) (AE1/AE3) can be used to identify

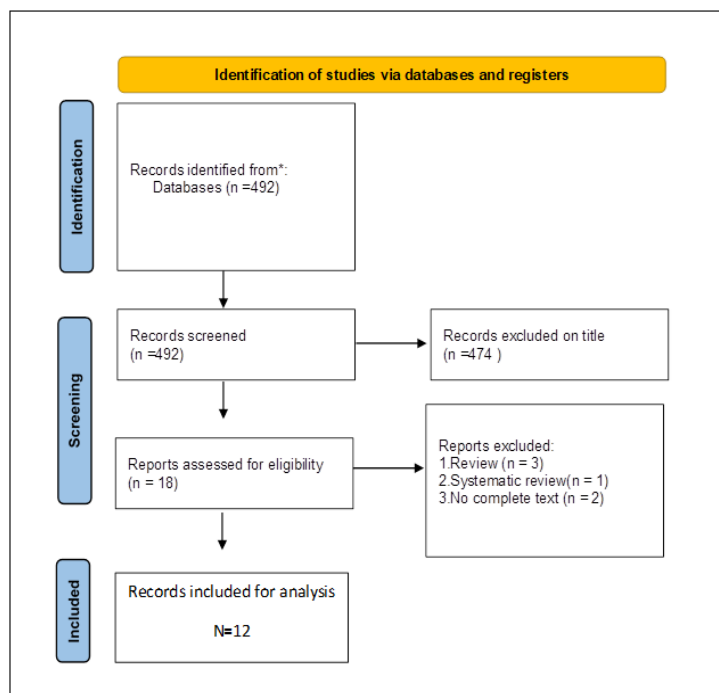


Figure 1. Prisma Flow Chart

a wide spectrum of both acidic and basic cytokeratin's and is commonly used as a prime marker to differentiate epithelial tumors from the nonepithelial ones with a high degree of accuracy even under low power standard light microscope. Since pan CK [AE1/AE3] is an epithelial marker it shows positivity for majority of epithelial tumors, more commonly in OSCC and PMODs. It has been shown that changes in the underlying connective tissue are reflected in the adjacent epithelium and also result in alterations in CK expressions.

In a study done by G Cserni et al, AE1/AE3 immunostaining in the basal layer was negative in the majority of cases except in severe dysplasia where 50% of cases showed a positively stained basal layer. CK 5 and CK 14 form the CK network in the basal layer. Reduced expression of one of this pair of CKs could result of stratified squamous epithelium. In the reduced detection of the other. The CK 14 positivity was confirmed by the immunostaining results, showing expression in the basal layer in all cases studied. Therefore, the lack of basal layer staining could represent a reduction in CK 5 expression frequently at an earlier stage in malignant transformation, reducing the detection by AE1/AE3 antibody of CK 14 expression [8].

AE1/AE3 antibody proved helpful in detecting malignant changes in clinically normal appearing mucosa (mirror image biopsy) in OSCC. For CK AE1/AE3, out of 7 cases, showing strong positive staining, one case showed more positivity in stratum spinosum and stratum superficiale and less intense staining in stratum granulosum and basale. This may be due to same pattern of keratin expression in stratum superficiale and stratum spinosum.

OSCC commonly metastasizes to the regional lymph nodes which are the first sites for tumor cells arrest that have invaded the peritumoral lymphatics and hence the strongest indicator of disease prognosis and outcome. For identification of an epithelial component, a mixture of antibody clones can be applied depending on its origin. The clones such as KL1, MNF116 and AE1/AE3 employed for detection of epithelial tumors. KL1 is recommended for detection of CKs 1, 2, 5, 6, 7, 8, 11, 14, 16, 17 and 18. Pan-CK is highly useful for screening of nodal micro metastasis MM even when low-power standard light microscopic examination is employed. Hence, this marker was preferred over other markers for detection of MICROMETASTASIS and ISOLATED TUMORCELLS [5].

Spindle Cell Carcinoma (SpCC) has been represented as a biphasic tumour with a common site to be affected was the upper aerodigestive tract. In a study by Ruchika Gupta et al reported three tumour-cell markers to which IHC analysis were done: CK, vimentin and smooth-muscle actin were done. CK positive was significantly greater in SCC than in spindle cell and squamous cell components of SpCC. The squamous cell areas of this carcinoma had a greater mean positivity for CK. The spindle cell areas plump to oval cells with nuclei elongated intermixed exhibiting both CK and vimentin positivity [7].

CK positive nodal structures cannot be equated with

metastatic nodal involvement always. Normal components of the lymph nodes may also stain with anti-CK antibodies. Plasma cells have also been reported to stain with CAM5.2 [monoclonal antibody] and in IHC, pan CK of unselected axillary lymph nodes from patients with Invasive Lobular Carcinoma has been shown to upstage these patients more often than those with ductal carcinoma [8].

CK and vimentin protein expression is a useful biomarker for PESC accurate diagnosis, but not prognosis. The present results demonstrate that CK, expressed chiefly in epithelial tumor cells, and vimentin, expressed always in spindle tumour cells, are useful diagnostic biomarkers in PESC, especially, the predictive power of the AE1/AE3 and vimentin proteins together was increased apparently than with single protein. However, the AE1/AE3, CK5/6 and vimentin proteins expressions didn't show any remarkable effects on PESC survival. Furthermore, no relationship was observed for the AE1/AE3 and vimentin proteins expression and age, gender, tumor location, gross appearance, lymph node metastasis, and TNM stage [6].

In SCC, recently immunocytochemical techniques have become widely used in cytopathology for the demonstration of a large number of various antigens (e.g., p53, CEA, EMA, LeuM1, B72.3, Lectin, CK, vimentin etc) in effusion and aspirate as an aid in differentiating malignant cells from benign cells. The detection of CK intermediate filament is widely used to identify tumors of epithelial origin. In present study CK positivity is found in 08/12 (66.66%) squamous cell carcinoma from aspirates [3].

In Colorectal cancer, monoclonal cytokeratin antibody AE1/AE3 to detect lymph node micrometastasis in Dukes' A and B colorectal cancer patients by using Immunohistochemistry. These patients usually treated with curative operation without any discovery of lymph nodes metastases using conventional histological techniques in the resected specimens. The results suggested that occult cancer cells were significantly stained with anti-CK antibody.

Over expression of panCK [AE1/AE3] can be used as a potential tool in diagnosis and hence used as a diagnostic marker. It is also used to see the progression of OSCC in response to specific treatment; so, it can also be used as prognostic marker. The advantage of this marker is, it has a high specificity, high sensitivity, long lead time, levels correlate with tumor burden, it has a short half-life, it is simple and cheap to test and it can be easily obtained. More studies are definitely needed in future with panCK [AE1/AE3] in PMODs, especially in different grades of severity of these, to have an excellent database for comparative and analytical studies.

More studies are also needed with regard to the TNM-staged OSCC and different grades of OSCC so that this marker can serve as a fool proof method in prognosis. The antibody reviewed in this study-panCK [AE1/AE3] constitutes a satisfactory diagnostic panel for assessing benign and premalignant oral lesions as they provide information about epithelial differentiation, proliferation, and cell-cycle regulation. AE1/AE3 antibody is not a useful marker in assessing tumour invasion as it does not

stain the basal layer in all cases. It is a satisfactory marker of squamous epithelium and has a useful application in distinguishing between SCC and malignancies of non-epithelial origin.

In conclusion, Thus, the current systematic review depicts the importance of the pan-CK marker-AE1/AE3 as a very crucial tumormarker. Though it is a very often-researched marker as far as SCC is concerned, studies are limited with regard to the same in PMODs. This review tends to point towards this lacuna, which if addressed, will showcase this marker as a very potent diagnostic and prognostic marker. The quality and quantity of its expression can serve as a map to target the therapies towards reversibility of PMODs and a quicker remission of frank malignancies. Also, innovative studies, in the same direction can be conducted and are needed in other epithelial potentially malignant lesions/conditions and tumors- benign/malignant like ameloblastoma, salivary gland tumors, extra-oral lesions etc.

Conflict of Interest Statement

The authors had no conflict of interest concerning the topic under consideration in this article.

References

1. Feller L, Lemmer J. Oral Squamous Cell Carcinoma: Epidemiology, Clinical Presentation and Treatment. *Journal of Cancer Therapy*. 2012 08 09;3(4):263-268. <https://doi.org/10.4236/jct.2012.34037>
2. Nw J, P J, Aa A. Squamous cell carcinoma and precursor lesions of the oral cavity: epidemiology and aetiology. *Periodontology* 2000. 2011 Oct;57(1). <https://doi.org/10.1111/j.1600-0757.2011.00401.x>
3. Bhadkariya A, Ramchandani A, Patel S, R.Purohit M. Study of Cytokeratin AE1/AE3 Reactivity in Squamous cell carcinoma in aspiration cytology. 2016;. <https://doi.org/10.5958/2394-6792.2016.00004.1>
4. Isha D, Simarpreet VS, Rajat B, NeenaSood, Ramanpreet KB, Neerja S. *Journal of Oral and Maxillofacial Pathology* | Published by Wolters Kluwer – Medknow. 2016 ;.
5. Gupta V, Ramani P. Histologic and immunohistochemical evaluation of mirror image biopsies in oral squamous cell carcinoma. *Journal of Oral Biology and Craniofacial Research*. 2016 Dec;6(3):194-197. <https://doi.org/10.1016/j.jobcr.2016.06.002>
6. Xm L, X S, Xk Z, Sj H, R C, S L, Df D, Xy Z, Jl L, Jw K, Dy Z, Y Z, Zm F, Ld W. The alterations of cytokeratin and vimentin protein expressions in primary esophageal spindle cell carcinoma. *BMC cancer*. 2018 04 02;18(1). <https://doi.org/10.1186/s12885-018-4301-1>
7. R G, S S, S H, S N, Bc D, I S, Ak M. Spindle cell carcinoma of head and neck: an immunohistochemical and molecular approach to its pathogenesis. *Journal of clinical pathology*. 2007 05;60(5). <https://doi.org/10.1136/jcp.2005.033589>
8. G C, S B, V V, H P, A S, R A, A R, P R, Jp B, C M, R B, Jm P, Ac I. The value of cytokeratin immunohistochemistry in the evaluation of axillary sentinel lymph nodes in patients with lobular breast carcinoma. *Journal of clinical pathology*. 2006 05;59(5). <https://doi.org/10.1136/jcp.2005.029991>
9. V V, T V, N R, K K, Nt M, M R. Analysis of Spatial Distribution and Prognostic Value of Different Pan Cytokeratin Immunostaining Intensities in Breast Tumor Tissue Sections. *International journal of molecular sciences*. 2020 06 22;21(12). <https://doi.org/10.3390/ijms21124434>
10. Bt R, Jl C, Dm A, Wp C, Nd F, M A, Nh C, Rl AJ, Sf DS, Ac A, Mj R, Op A. Primary melanoma of the oral cavity: A multi-institutional retrospective analysis in Brazil. *Medicina oral, patologia oral y cirugia bucal*. 2021 05 01;26(3). <https://doi.org/10.4317/medoral.24240>
11. Zhou Z, Rieger N, Ruszkiewicz A, Wang G, Wan D. Detection of lymph nodes micrometastases in Dukes' A and B colorectal cancer using anti-cytokeratin antibodies AE1/AE3. *World Journal of Gastroenterology*. 2005 06 21;11(23):3640-3643. <https://doi.org/10.3748/wjg.v11.i23.3640>
12. Mălin RD, Ioniță E, Osman I, Mogoantă CA, Cioroianu L, Ciolofan S, Anghelina F, Enăchescu M, Mălin RD, Ioniță E, Osman I. Histopathological and immunohistochemical study of laterocervical lymph node metastases of unknown primary origin. *Rom J Morphol Embryol*. 2012 Jan 1;53(2):337-42.
13. Farrar M, Sandison A, Peston D, Gailani M. Immunocytochemical analysis of AE1/AE3, CK 14, Ki-67 and p53 expression in benign, premalignant and malignant oral tissue to establish putative markers for progression of oral carcinoma. *British Journal of Biomedical Science*. 2004;61(3):117-124. <https://doi.org/10.1080/09674845.2004.11732655>
14. Ranganathan K, Kavitha R, Sawant SS, Vaidya MM. Cytokeratin expression in oral submucous fibrosis--an immunohistochemical study. *Journal of Oral Pathology & Medicine: Official Publication of the International Association of Oral Pathologists and the American Academy of Oral Pathology*. 2006 01;35(1):25-32. <https://doi.org/10.1111/j.1600-0714.2005.00366.x>



This work is licensed under a Creative Commons Attribution-Non Commercial 4.0 International License.