

# Malignant Melanoma of the Palate: Report of a Metastatic Case

Mel Valerie B. Cruz-Ordinario, Carlo Antonio Dg. Boado, Agnes E. Gorospe

St. Luke's Medical Center - Quezon City, Philippines.

## Abstract

Primary malignant melanoma of the oral cavity is a rare malignancy with an incidence of 0.2 to 8% of all melanomas. Melanoma arises from the malignant transformation of the melanocyte and cutaneous melanomas are the most common followed by ocular, mucosal and melanoma of unknown primary site. Here we present a case of a 54 year old male who presented with a pigmented lesion on the palate, a type of mucosal melanoma. Due to the rarity of this disease, it is infrequently studied. Hence, epidemiology, etiology, pathogenesis and prognosis still remains to be less understood than cutaneous melanoma. Early diagnosis is warranted as therapeutic options are limited for advanced and metastatic disease. Surgery is the primary therapeutic management and complete resection is the main goal. If not feasible, radiotherapy may also be employed to achieve local control and enhance locoregional response. Prognosis is generally poor for metastatic disease and there are no guidelines yet on the use of systemic therapy.

**Keywords:** Melanoma- palate- Case report

*Asian Pac J Cancer Care*, 7 (4), 757-761

Submission Date: 08/21/2022

Acceptance Date: 10/11/2022

## Introduction

Primary oral malignant melanoma (POM) is a rare, very aggressive neoplasm of melanocytic origin characterized by the proliferation of atypical melanocytes at the epithelial-connective tissue interface, associated with upward migration into the epithelium and by invasion of the underlying connective tissue. It presents as bluish black to tan-brown colored lesion. It accounts 0.2 to 8% of all melanomas, 1.6% of all head and neck malignancies, and 0.5% of all oral neoplasia [1,2].

Melanoma can be curable when full excision is made after early diagnosis. However, treatment options are limited for metastatic disease and survival is generally poor [3].

### Report of a Case

A 54-year-old male from Papua New Guinea patient was referred to our institution with the chief complaint of pain, swelling and bleeding in the palate.

History started one year prior to admission when patient noted a progressively enlarging nodule on the left side of the palate. Initially, the nodule was noted to be hyperpigmented, non-movable and painless. He noted

progressive enlargement in the interval history and noted intermittent episodes of unquantified bleeding everytime he chews betel nut. Since then, the lesion increased in size with noted points of bleeding and loss of teeth. The mass still was painless and the patient did not note of difficulty opening or closing his mouth. Patient's relatives noted progressive weight loss. There was no associated hearing loss, dizziness, diplopia, weakness, numbness and difficulty of breathing, fever and dysphagia.

He consulted at a hospital in their locality but was advised to consult in our country due to lack of facilities. The review of systems was unremarkable.

The patient has no history of hypertension, diabetes, asthma or COPD. He has an 8 pack-year history of smoking and had the habit of chewing betel nut since childhood which was popular in Papua New Guinea. He also wore dentures for an unrecalled duration. He has no familial cancer background.

The clinical examination revealed no cranial nerve deficits, no palpable cervical and regional lymphadenopathy and a hyperpigmented bleeding mass on the palate, friable, ulcerated which measures 6 x 6

### Corresponding Author:

Dr. Mel Valerie B. Cruz-Ordinario  
St. Luke's Medical Center - Quezon City, Philippines.  
Email: melvalericacruz@gmail.com

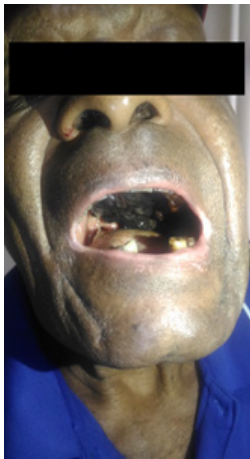

Figure 1. Black Mucosal Growth Involving the Palate

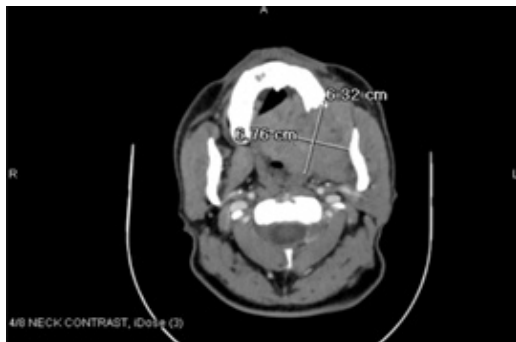


Figure 2. Neck CT Scan (Axial Cut) Showing Enlarged Hard Palate Mass

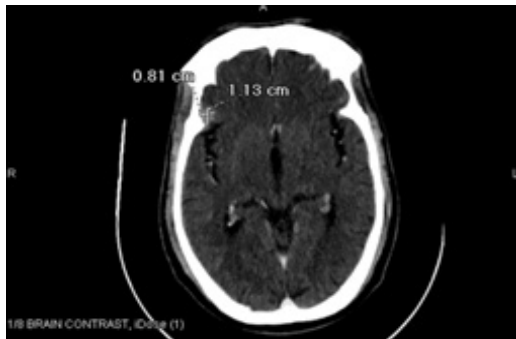


Figure 3. Cranial CT Scan (Axial Cut) Showing Right Frontal Region Lesion

centimeters (Figure 1).

The patient was admitted and referred to Otolaryngology, Head and Neck Surgery Service. Transfusion of 2 units PRBC was done initially due to hemoglobin of 6.3 which was attributed to the intermittent bleeding.

CT scan neck was done which showed an ill-defined heterogeneously enhancing mass centered in the left hard palate with soft tissue encroachment and bony erosion which may represent a neoplastic process. The mass extended to the maxillary sinus with bulging to the left nasal cavity at the level of the middle meatus with destruction of the inferior maxillary sinus wall as well as the second and third maxillary molar tooth on the left (#15 and #16) Bilateral ethmoid and right maxillary mucosal

sinus disease, obstructed left ostiomeatal unit and enlarged left level IIA lymph node (Figure 2).

The CT of the brain revealed a solid enhancing lesion in the right inferior frontal region which was worrisome for metastatic focus, hypodense focus in the right frontal white matter and probably in the left side of the pons may be secondary to focal ischemia (Figure 3).

Repeat CBC showed hemoglobin of 8.7 for which 2 units of packed RBC was again transfused. Patient was referred to Medical Oncology and a metastatic work-up (chest CT scan and abdominal CT) was done which showed prominent-sized bilateral inguinal lymph nodes, prostatomegaly with few concretions and multiple vari-sized non-calcified nodules in both lungs, patchy areas of ground-glass and reticular densities in the right lung may be infectious or inflammatory in nature. Subsegmental atelectasis or fibrosis in the right middle and both lower lobes (Figure 4 and 5).

Further work-up showed increased osteoblastic activity in the maxilla and left infraorbital, likely due to tumor extension (Figure 6).

For the patient, a wedge biopsy of the palate mass was done which showed a 6x6 well defined friable mass with blackened blood clots on the hard palate with plane of cleavage from the palate with noted infiltration to the left maxillary alveolar area and an intranasal mass coming from the left ethmoidal region pushing the middle turbinate medially. Specimen labeled as "palatal mass", which consisted of several dark brown to black, irregular, soft tissue fragments with an aggregate measurement of 2.5x2.5x0.6 cm and specimen labeled as "maxillary mass, left", which consists of several dark brown to black, irregular, soft tissue fragments with blood clots with an aggregate measurement of 2.5x2x0.5cm were submitted. Microsections showed epithelioid to spindle cells arranged in infiltrating small clusters and sheets with dense pigmentation and significant nuclear pleomorphism and increased mitotic activity. Findings were consistent with malignant melanoma with bone erosion (Figure 7).

Patient was staged as stage IV disease (T4bN1M1) (lung and brain). Prognosis explained via the patient's interpreter that overall prognosis was not good due to malignant behavior, extent and location of the mass. Patient refused further treatment and opted to have

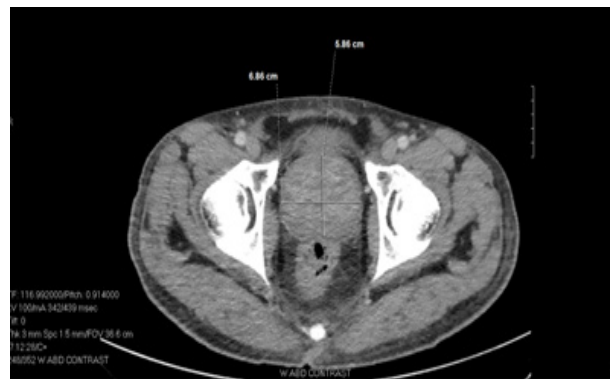

Figure 4. CT Scan of the Abdomen (Axial Cut) Showing Enlarged Prostate

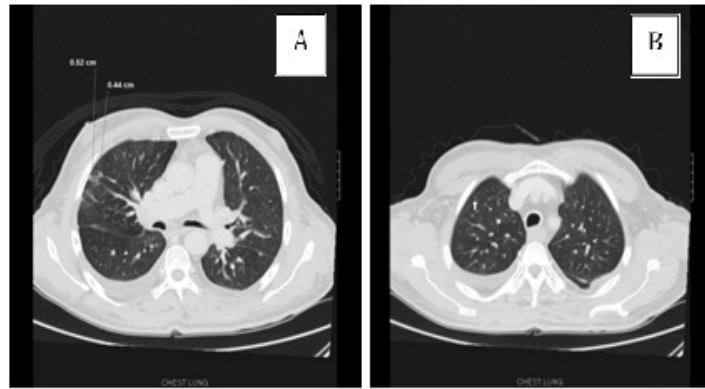


Figure 5. A and B; CT Scan of the Lung (Axial Cut) Showing Multiple Vari-sized Non-calcified Nodules in Both Lungs

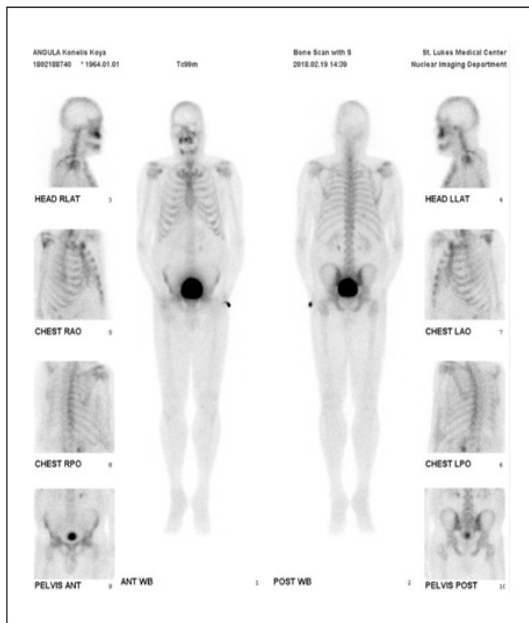


Figure 6. Bone Scan with SPECT-CT

palliative care and he was eventually discharged stable.

## Discussion

Melanoma arises from the malignant transformation of the melanocyte, the cell responsible for the production of the pigment melanin. The most common location is the hair follicle-bearing skin arising from melanocytes at the dermal/epidermal junction. Cutaneous melanomas are the most common followed by ocular, mucosal and melanoma of unknown primary site [4]. Our patient presented with a lesion of the palate, a case of primary oral malignant melanoma which represents 0.2–8% of all melanomas and 0.5% of all oral malignancies [2]. This type of melanoma develops from the melanocytes found in the basal layer of the oral mucosa.

Etiology and Risk factors vary across different types of melanoma. Ultraviolet light exposure has been implicated as a major etiologic factor [4]. There is scarce data on the average daily ambient ultraviolet radiation level of each country. Estimated population-weighted average daily

ambient UVR level (in  $J/m^2$ ) for the years 1997–2003 for Papua new guinea is 5377 [5]. In a study by Bykov et al in 1998, a dose of 400  $J/m^2$  solar simulated radiation caused high levels of pyrimidine dimers which may explain why patients with DNA repair syndrome preferentially develop skin cancer [6]. However, unlike cutaneous melanoma, in mucosal melanoma UV light is not an apparent risk factor. The etiology and pathogenesis still remain unclear [7]. Distinct molecular features such as lower incidence of BRAF oncogene mutations and higher KIT oncogene mutations suggest variant genetic etiology [7].

Areca nut, commonly referred to as Betel Nut, has been implicated as one of the possible causes of oral melanoma. Due to its addictive property, patient has been known to chew betel nut since childhood. As early as 1921, medical literature contains many references to cancer of the mouth in betelnut chewers. These observations were seen in India, Africa and some islands in the Pacific Ocean [8]. High chewing prevalence has been found among the Palauans of the West Pacific. An inter-country Asian Betel-quid Consortium study (ABC study) showed chewing rates among men is 10.7–43.6%, which is significantly higher than in women, 1.8–34.9% [9]. The most important consideration is the relation between areca nut use and the development of mouth cancer, particularly oral squamous cell carcinoma and its precursors leukoplakia and submucous fibrosis [10]. There is limited data on association of betel nut and primary oral malignant melanoma but this is possibly because of the rarity of the disease.

The classic appearance of melanoma is summarized by the mnemonic ABCD for asymmetry, border irregularity, color variation and diameter  $>6$  mm [4]. They may present as dark-brown, bluish black or black mucosal discoloration and may be solitary or multiple, flat and/or elevated, irregular borders and no clear demarcation exists between the tumor and the adjacent tissues. Pain was the most common referred symptom [11]. This patient presented with a hyperpigmented bleeding mass on the palate, friable, ulcerated which measures 6 x 6 centimeters. He lost some of his teeth but denies any pain.

Histologically, it would appear as an invasive pattern of growth with the tumor cells often appearing as densely

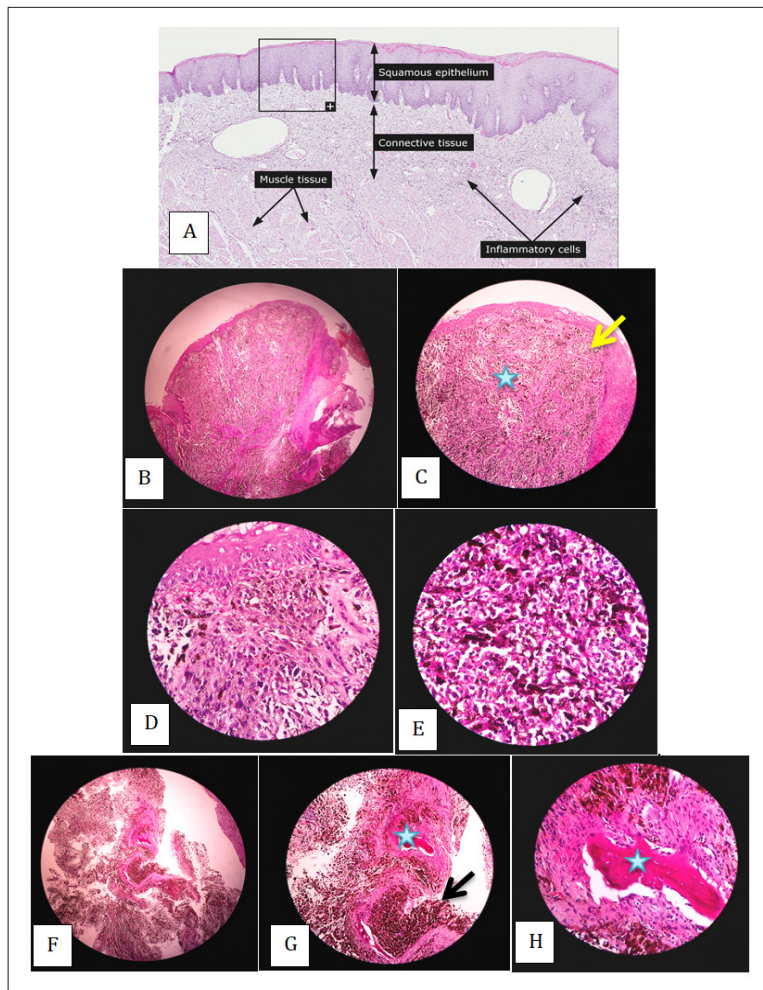


Figure 7. A. Example of a Normal Mucosa (for comparison). B. Scanner view of specimen “A”. C. Higher magnification. Stratified squamous nonkeratinizing epithelium of the oral mucosa (yellow arrow). Pigmented lesion (blue star) which has distorted the normal connective tissue layer. D. Scattered pigmented cells beneath the epithelium. E. On high power view. Sheets of malignant pigmented epithelioid cells with enlarged, hyperchromatic, round to oval nuclei, some with prominent cherry- red nucleolus, and ample amount of clear to eosinophilic cytoplasm characteristic of a melanoma. F. Scanner view of specimen “B”. G. Higher magnification. Malignant pigmented lesion (black arrow). Bony tissue fragment (blue star). H. Malignant cells had already encroached upon the normal bony tissue. This is interpreted as malignant melanoma with bone erosion.

packed epithelioid or sometimes sarcomatoid cells with eosinophilic cytoplasm. Varying degrees of cellular pleomorphism can be seen [11].

The pattern of lymph node metastasis of oral melanoma has not been well documented. In a study by Ram et al, in 2010, correlation between tumor thickness and the incidence of cervical lymph node metastasis has been noted. Greater tumor thickness was associated with a more advanced stage. Metastasis via hematogenous route may occur early to the lungs, liver, brain or bone and later metastatic spread to the local lymph node occurs. Distant metastatic spread occurs within 6 to 78 months [11]. Our patient presented with lung and brain lesions upon diagnosis.

Radical surgery is the treatment of choice for oral melanoma with options to do elective neck dissection. This can be combined with radiotherapy and chemotherapy. For inoperable tumors, or the elderly, radiotherapy alone is the preferred method. Chemotherapy is generally

employed on metastatic disease [11]. Injection of cutaneous melanoma with BCG vaccine and treatment with interferon and cimetidine has been described [12, 13].

Immunologic studies with Human malignant melanoma has been described in the 1970s [14]. Pembrolizumab, A humanized monoclonal immunoglobulin (Ig) G4 antibody directed against human cell surface receptor PD-1 (programmed death-1 or programmed cell death-1) with potential immune checkpoint inhibitory and antineoplastic activities [15]. KEYNOTE-001, 002, 006 studies showed that patients with advance mucosal melanoma (84 out of 1567) showed response with pembrolizumab. Some patients with mucosal melanoma showed complete response [16].

The prognosis is generally poor with 31% of patients with localized disease surviving for 5 years falling to 5.2% when there is metastasis. As patients usually are diagnosed with locally advanced disease, high clinical index of suspicion and good history and complete physical examination cannot be overemphasized.

## Acknowledgements

We are indebted to the Institutes of Pathology, Radiology and Nuclear Medicine for the images shown in this report.

## References

1. Kumar A, Bindal R, Shetty DC, Singh HP. Primary oral malignant melanoma: Clinicopathological series of four cases. *Dental Research Journal*. 2012 05;9(3):338-344.
2. Rani GS, Kumar TV, Kolasani B, Begum MR, Priya Srinivasan A. Primary malignant melanoma of maxilla: report of a case with discussion. *Case Reports in Dentistry*. 2014;2014:624306. <https://doi.org/10.1155/2014/624306>
3. Rimal J, DP K, Kumbargere Nagraj S, Ongole R, Shrestha A. Intra-oral amelanotic malignant melanoma: Report of a case and review of literature. *Journal of Nepal Dental Association*. 2009 01 01;10:49-52.
4. De Vita, Hellman & Rosenberg's Cancer: Principles and Practice of Oncology, 10<sup>th</sup> edition. Wolters Kluwer Health, 2018.
5. Exposure to solar ultraviolet (UV) radiation. Data by country. World health organization. 2016.
6. Bykov VJ, Jansen CT, Hemminki K. High levels of dipyrimidine dimers are induced in human skin by solar-simulating UV radiation. *Cancer Epidemiology, Biomarkers & Prevention: A Publication of the American Association for Cancer Research, Cosponsored by the American Society of Preventive Oncology*. 1998 03;7(3):199-202.
7. Spencer KR, Mehnert JM. Mucosal Melanoma: Epidemiology, Biology and Treatment. *Cancer Treatment and Research*. 2016;167:295-320. [https://doi.org/10.1007/978-3-319-22539-5\\_13](https://doi.org/10.1007/978-3-319-22539-5_13)
8. Ellis, Aller G. Betelnut Chewing and its Effects, Including Cancer of the Mouth. *Arch Intern Med (Chic)*. 1921;28(3):252-267.
9. Sharan RN, Mehrotra R, Choudhury Y, Asotra K. Association of betel nut with carcinogenesis: revisit with a clinical perspective. *PloS One*. 2012;7(8):e42759. <https://doi.org/10.1371/journal.pone.0042759>
10. Warnakulasuriya S, Trivedy C, Peters TJ. Areca nut use: an independent risk factor for oral cancer. *BMJ (Clinical research ed.)*. 2002 04 06;324(7341):799-800. <https://doi.org/10.1136/bmj.324.7341.799>
11. Ram H, Mohammad S, Husain N, Devi S, Gupta PN. Metastatic malignant melanoma of palate: A review of literature and report of an unusual case. *National Journal of Maxillofacial Surgery*. 2010;1(1):63-66. <https://doi.org/10.4103/0975-5950.69165>
12. Flodgren P, Borgström S, Jönsson PE, Lindström C, Sjögren HO. Metastatic malignant melanoma: regression induced by combined treatment with interferon [HuIFN-alpha(Le)] and cimetidine. *International Journal of Cancer*. 1983 Dec 15;32(6):657-665. <https://doi.org/10.1002/ijc.2910320603>
13. Smyth AG, Ward-Booth RP, Avery BS, To EW. Malignant melanoma of the oral cavity--an increasing clinical diagnosis?. *The British Journal of Oral & Maxillofacial Surgery*. 1993 08;31(4):230-235. [https://doi.org/10.1016/0266-4356\(93\)90145-m](https://doi.org/10.1016/0266-4356(93)90145-m)
14. Morton DL, Eilber FR, Joseph WL, Wood WC, Trahan E, Ketcham AS. Immunological factors in human sarcomas and melanomas: a rational basis for immunotherapy. *Annals of Surgery*. 1970 Oct;172(4):740-749. <https://doi.org/10.1097/0000658-197010000-00018>
15. National Cancer Institute Dictionary.
16. Immunotherapy, pembrolizumab, is active against mucosal melanoma tumors and prolongs survival for patients with bladder cancer. The European Cancer Organisation. January 29, 2017. <https://www.sciencedaily.com>



This work is licensed under a Creative Commons Attribution-Non Commercial 4.0 International License.